Phil. Trans. R. Soc. Lond. B **310**, 109–122 (1985) [109]
Printed in Great Britain

CENTRAL PATHWAYS OF THE NERVES OF THE ARMS AND MANTLE OF *OCTOPUS*

BY B. U. BUDELMANN[1] AND J. Z. YOUNG, F.R.S.[2]

[1] *Zoological Institute, University of Regensburg, D* 8400 *Regensburg, Federal Republic of Germany*
[2] *The Wellcome Institute for the History of Medicine,* 183 *Euston Road, London NW*1 2*BP, U.K.*

(*Received* 4 *July* 1984)

[Plates 1–10]

CONTENTS

Vol. 310. B 1143 [published 31 August 1985

Centripetal cobalt filling of a brachial nerve of *Octopus* gave further information about the organization of its tactile learning system. Efferent fibres pass from the posterior buccal and subvertical lobes direct to the arms. Afferent fibres from the arms pass to the lateral and median inferior frontal lobes, others to the lateral and median superior frontal lobes, and a third set to the subvertical lobe. None reach to the vertical or subfrontal lobes.

Many somata and afferent fibres were filled in the magnocellular lobes after filling either the brachial or pallial nerves. This is probably a region from which escape reactions are initiated. The lower part of the median basal lobe also receives afferents from both these nerves and a few somata were filled at the lower edge of this lobe. It probably controls the magnocellular lobe, lying below it.

After filling of a brachial nerve, or the pallial nerve, somata were filled in both the anterior and posterior chromatophore lobes, but few or no afferent fibres were filled in these lobes.

After filling of a brachial nerve many somata and afferent fibres were filled in the prebrachial and brachial lobes and in the anterior pedal lobe, and many fine afferent fibres and a few somata were filled in the superior buccal lobe. After filling of the pallial nerve some filled fibres run forwards to the brachial lobe, but no somata were filled there. No filled fibres from either the brachial or pallial nerves were seen proceeding towards the optic lobes.

1. INTRODUCTION

Little is known about the functional components of the fibre tracts that have been described in the suboesophageal lobes of the *Octopus* central nervous system (Young 1971). Some of the afferent pathways have been defined following degeneration after section of the nerves. This technique, however, has not allowed identification of the somata of the efferent fibres. This is made possible by filling with cobalt and this technique has been used for the oculomotor and statocyst nerves and has shown that the motoneurons for the eye muscles lie in the anterior lateral pedal lobe (Budelmann & Young 1984). Many somata of efferent fibres to the statocyst also lie here and others are in the magnocellular lobe (Budelmann & Young 1984).

Centripetal cobalt filling of the brachial nerves and pallial nerve have now shown further details of the organization of their motoneurons and of afferent pathways from their periphery. As expected, there are concentrations of neurons for the arms and mantle in the brachial and palliovisceral lobes, respectively. In addition, we have found long efferent pathways from the magnocellular lobe passing both forwards to the brachial and backwards to the pallial nerves. This is evidently a centre controlling the movement of the whole animal, perhaps especially for escape.

A special reason for studying the efferent fibres to the arms is that they are responsible for the control of the movements of learned tactile discriminations (Young 1983). Centripetal cobalt filling of the brachial nerves has now shown somata stained in the posterior buccal lobe, which we have thus identified as the final pathway for the learned responses. Furthermore, the afferent fibres from the arms have now been shown to reach the superior frontal and subvertical lobes. This is of special interest since the vertical lobe system also plays a part in tactile learning (Young 1983).

2. MATERIAL AND METHODS

Eleven *Octopus vulgaris* (55–140 g, both males and females) were used in this study. The animals were obtained from the Gulf of Naples, kept at the Stazione Zoologica di Napoli for about two weeks, and then brought to the University of Regensburg. There the animals were kept separately in small tanks (20–30 l) in a closed circulation of artificial seawater at 15–18 °C.

Experiments were done with the nerves of both the left and right side. The terminology of the *Octopus* central nervous system is based on Young (1971).

2.1. *Centripetal cobalt filling of the brachial and palliovisceral nerves*

Isolated head preparations with the body and arms removed were kept in seawater. For the brachial nerves (six preparations), the buccal mass was removed, exposing all eight brachial nerves inside the buccal cavity. In all preparations the nerve of the third arm was used to allow comparison; there is no reason to believe that the results will differ for the various brachial nerves. The nerve was dissected from its surrounding tissue and cut 2–3 mm before entering the tissue in front of the brain. For the pallial nerve (five preparations), the inside of the muscular capsule surrounding the digestive gland was exposed and the pallial nerve dissected from its surrounding tissue, and cut 2–3 mm beyond the point where it is joined by the collar nerve.

For the treatment of the cut end of the nerve and the subsequent cobalt filling technique (including some limits of evidence) see Budelmann & Young (1984). Improvements of the results were obtained with a double intensification technique: after a first weak intensification with a modified Timm's method (Tyrer & Bell 1974), the c.n.s. sections were transferred from the Timm's solution into distilled water at the same temperature and thereafter into 70% (by volume) alcohol where the sections were kept overnight. The following day, the sections were intensified for a second time with the same method. For subsequent treatment see Budelmann & Young (1984).

3. RESULTS

3.1. *Centripetal cobalt filling of the brachial nerves*

3.1.1. *Supraoesophageal lobes*

A lateral view of the whole brain before sectioning shows massive filling of fibres in the cerebrobrachial connective after filling of the brachial nerve (figures 1 and 2, plate 1). The fibres spread out upwards throughout the inferior frontal system (figure 2). Sections show that the superior buccal lobe contains many fine filled fibres, presumably afferents. They are distributed throughout the neuropil on both sides. A few somata are filled on the same side (figures 5 and 6, plate 2; figures 12 and 15, plate 3).

Filled somata of the posterior buccal lobe were already seen from below before sectioning. Large somata are filled all along the medial side of the floor of the lobe. The largest reach 40 μm in diameter. In sections they can be seen to lie close to the base of the subfrontal lobe, some of them mixed with the most ventral cells of the latter (figures 7, 8 and 10). This is the region that has been found to be necessary for the establishment of learned tactile responses (Wells & Young 1975). These large cells that send axons direct to the arms extend all along the floor of the lobe, to the level where the posterior buccal joins the subvertical lobe (figures 14 and

17). The few fibres that are filled in the posterior buccal lobe are mostly large and all of them are presumed to be the axons of these cells (but see Discussion). The position of these filled somata is also well seen in sagittal sections (figures 12 and 13).

In the lateral inferior frontal lobe there are many fine filled fibres, spreading throughout the neuropil (figures 7–9). Bundles of fibres continue on into the median inferior frontal lobe (figures 7 and 10). Here they divide up to make the network of interweaving bundles that is characteristic of the lobe. Few details of the branching pattern have been made out. Many of the fibres show the coarse swellings that distinguish them in silver preparations (figure 11; Young 1971). Many fibres reach across the midline to all parts of the opposite lobe (figure 10). These are, of course, the fibres ensuring that information collected by an arm on one side is available to the other, so that both may learn on a basis of unilateral experience.

No somata are filled in the lateral or median inferior frontal lobes nor are there any filled somata within the subfrontal lobe itself. The larger cells of the subfrontal lobe, therefore, do not project to the arms but only as far as the posterior buccal lobe.

Of special interest is the filling of fibres entering the superior frontal and vertical lobe system. Fine fibres, presumably afferents, can be seen proceeding in the interfrontal tract from the back of the posterior buccal lobe to the lateral superior frontal lobe (figures 12 and 13). Some of these fibres pass on to the median superior frontal lobe. Here they are seen as scattered fibres among the interweaving bundles of fibres that stimulate the axons passing to the vertical lobes.

A second set of filled fibres from the brachial nerve passes in the cerebral tract upwards and backwards to the subvertical lobe (figures 16 and 18). Filled fibres occur sparsely throughout this lobe, up to the base of the vertical lobe, but have not been seen entering the latter. Some large fibres are filled at the centre of the subvertical lobe. They can be followed backwards, upwards and laterally, giving dendritic branches to the neuropil. These large fibres are therefore probably efferents by which the vertical lobe system exercises learned control of the arms (Young 1983). Their somata have not been seen but may lie far laterally in the lateral subvertical lobes (see §4.1.2.).

DESCRIPTION OF PLATE 1

Whole mounts of the *Octopus* brain after centripetal cobalt filling of the third brachial nerve.

FIGURES 1 AND 2. Lateral views of the brain showing somata in the brachial, anterior chromatophore, anterior pedal, magnocellular and palliovisceral lobes. Afferent fibres are seen in the cerebrobrachial tract proceeding to the inferior frontal lobe.

FIGURE 3. Dorsal view of the suboesophageal lobes of the brain showing somata in the ipsilateral (and a few in the contralateral) brachial lobe, and in the anterior chromatophore, anterior pedal and palliovisceral lobes.

FIGURE 4. Ventral view of the brain showing fibres in the ipsilateral and contralateral brachiopalliovisceral lobe connectives.

DESCRIPTION OF PLATE 2

Transverse sections of the supraoesophageal lobes of the *Octopus* brain after centripetal cobalt filling of the third brachial nerve.

FIGURES 5 AND 6. Afferent fibres and few somata in the superior buccal lobe.

FIGURES 7–11. Afferent fibres in the lateral and median inferior frontal and in the posterior buccal lobes, and somata along the medial side of the posterior buccal lobe (close to the subfrontal lobe). Figure 10 shows bundles of afferent fibres running to the median inferior frontal lobe; many of these fibres cross the midline and spread out in the contralateral side of the lobe. Figure 11 (high power of figure 10) shows afferent fibres with coarse swellings.

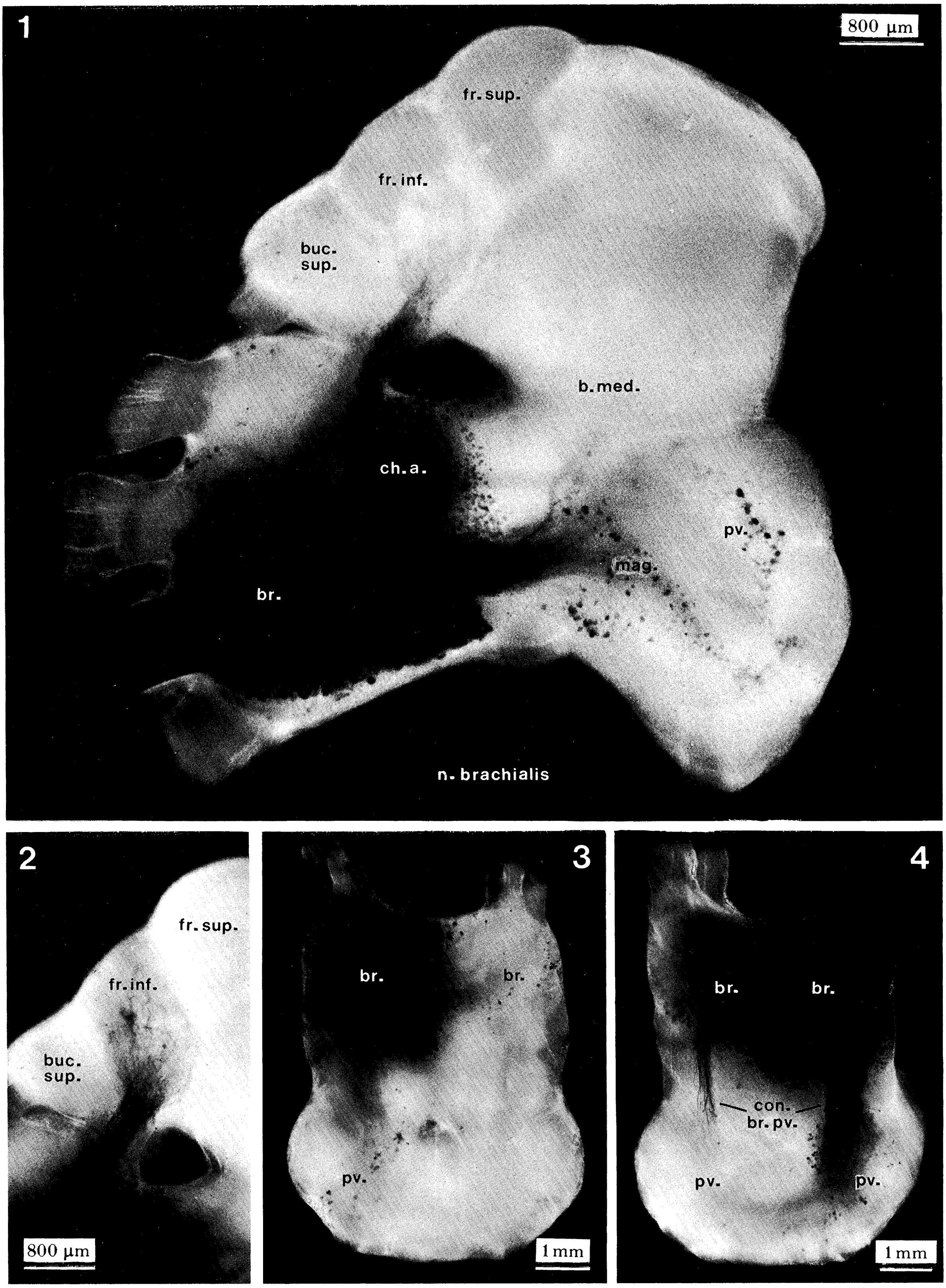

FIGURES 1–4. For description see opposite.

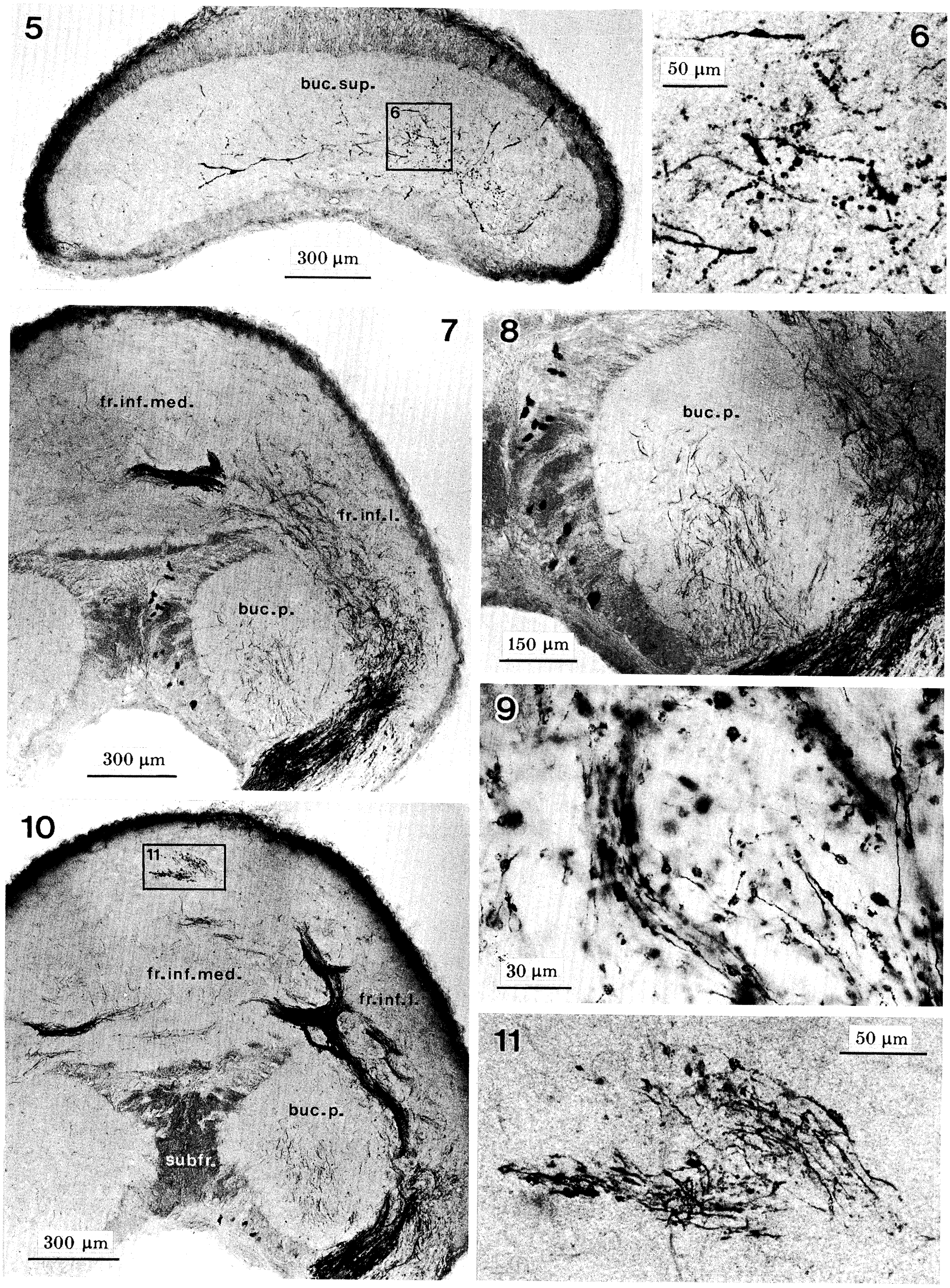

FIGURE 5–11. For description see p. 112.

12

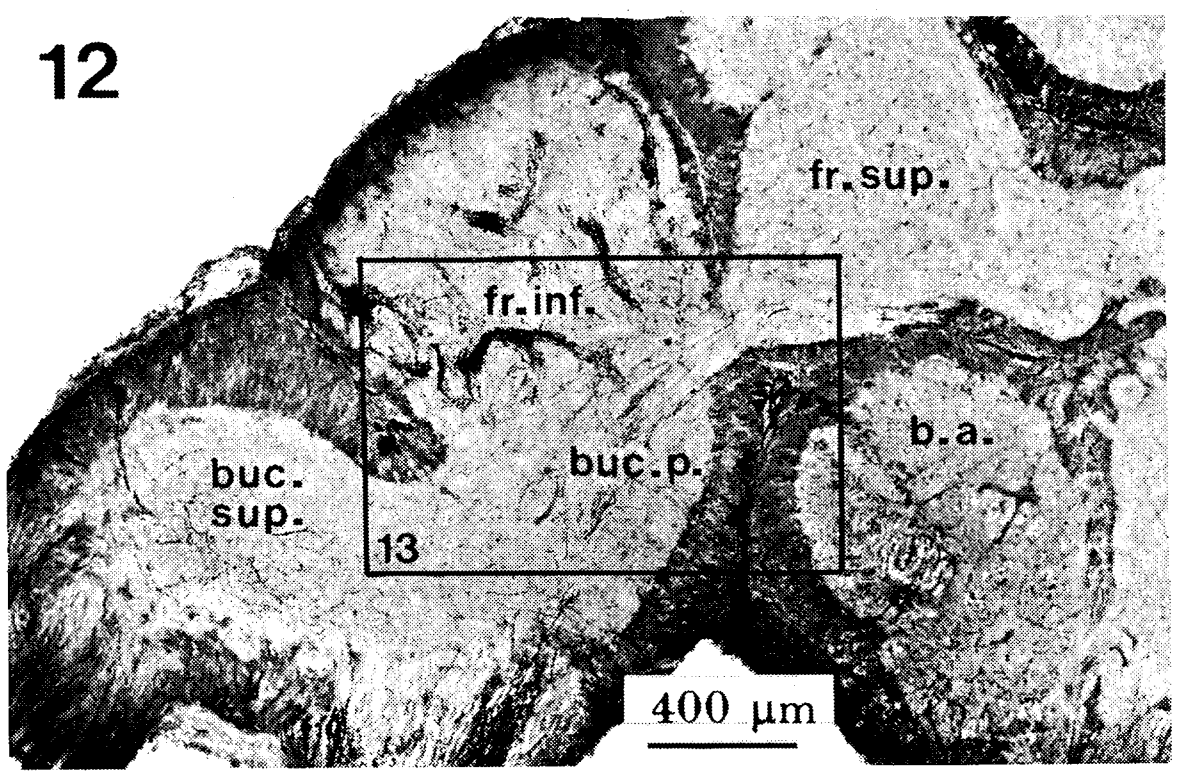

13



14

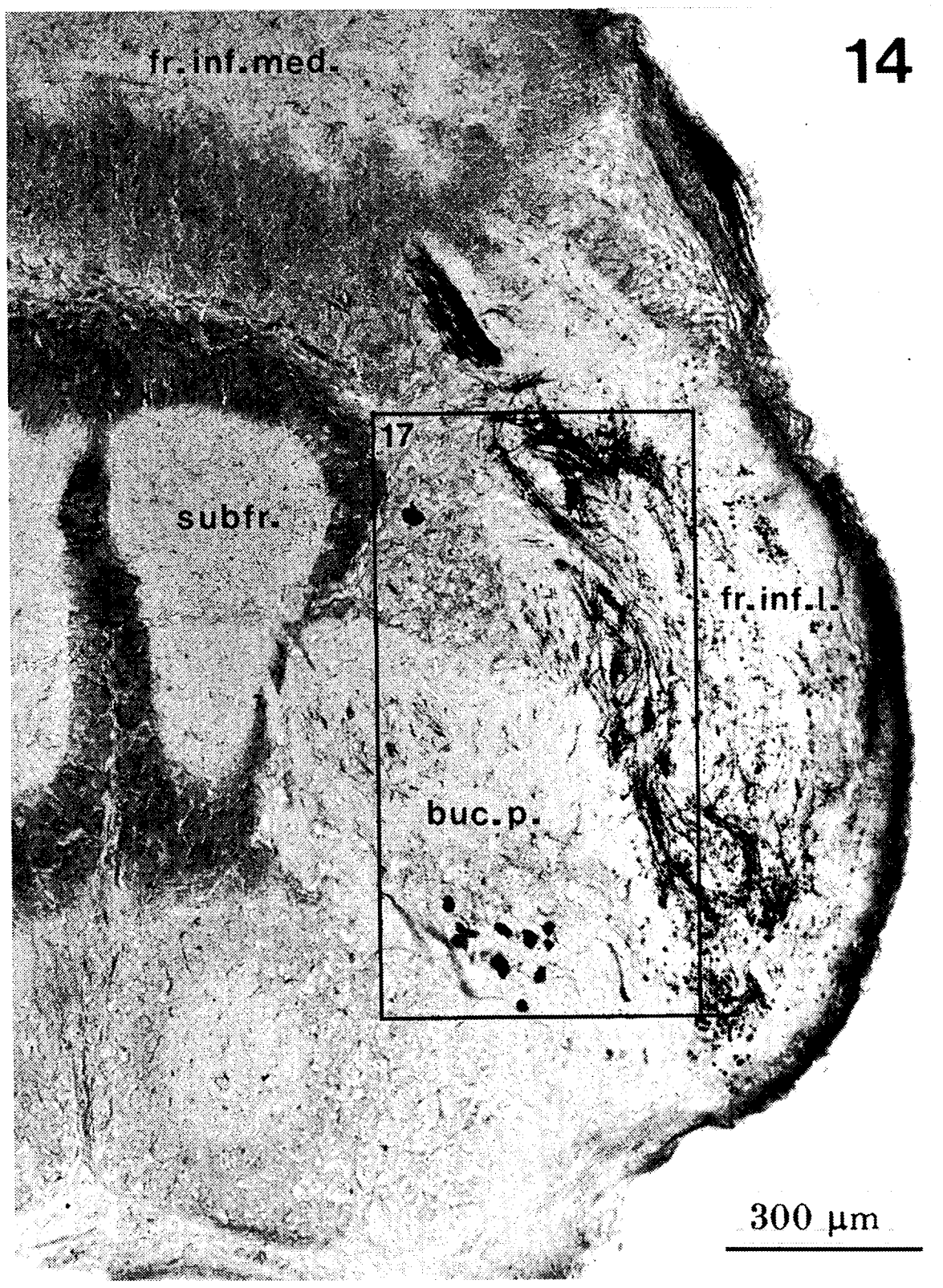

15

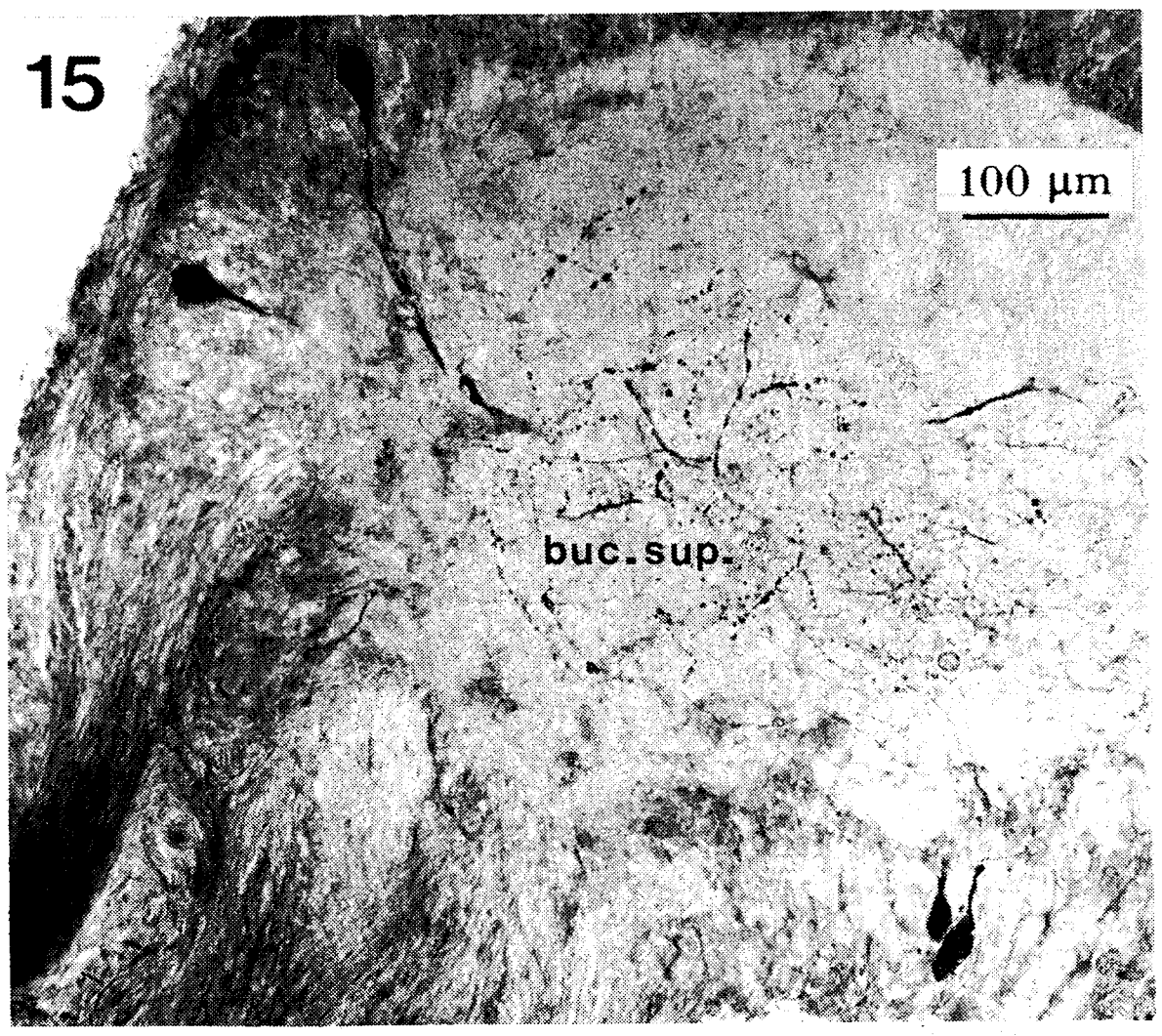

16

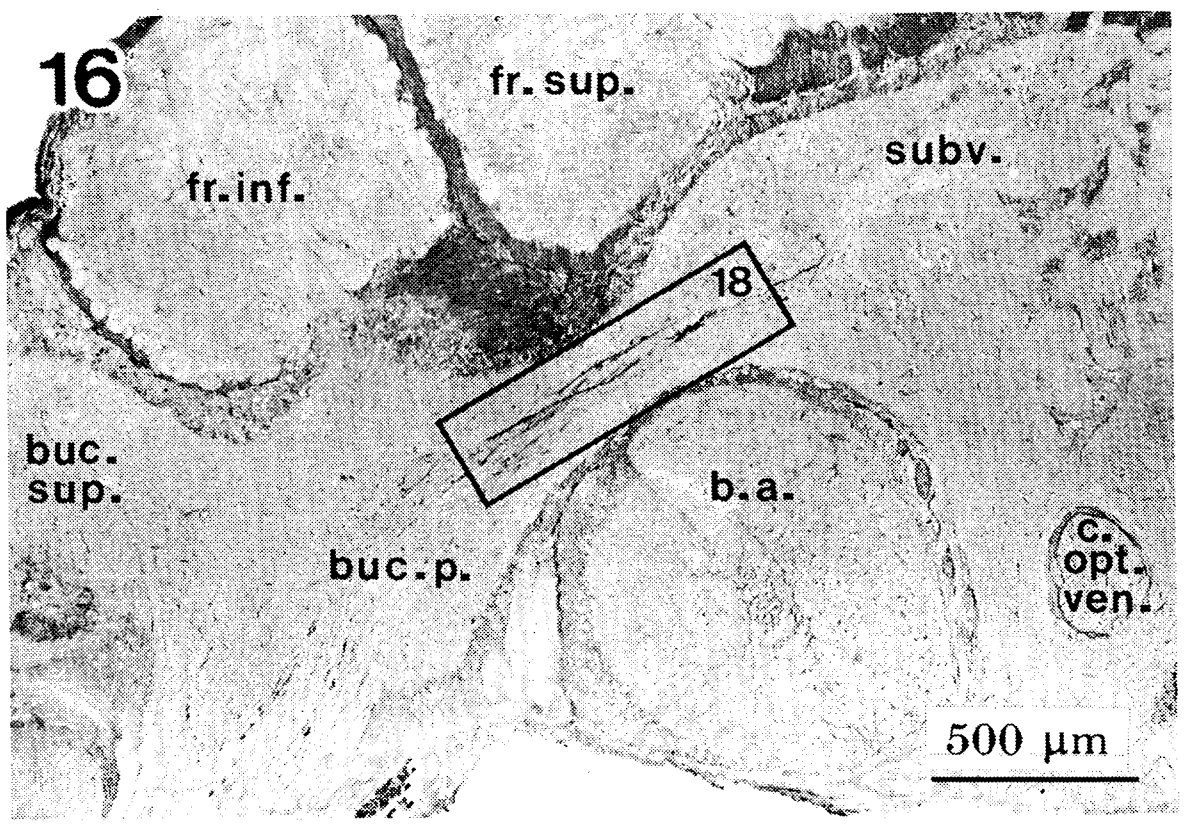

17

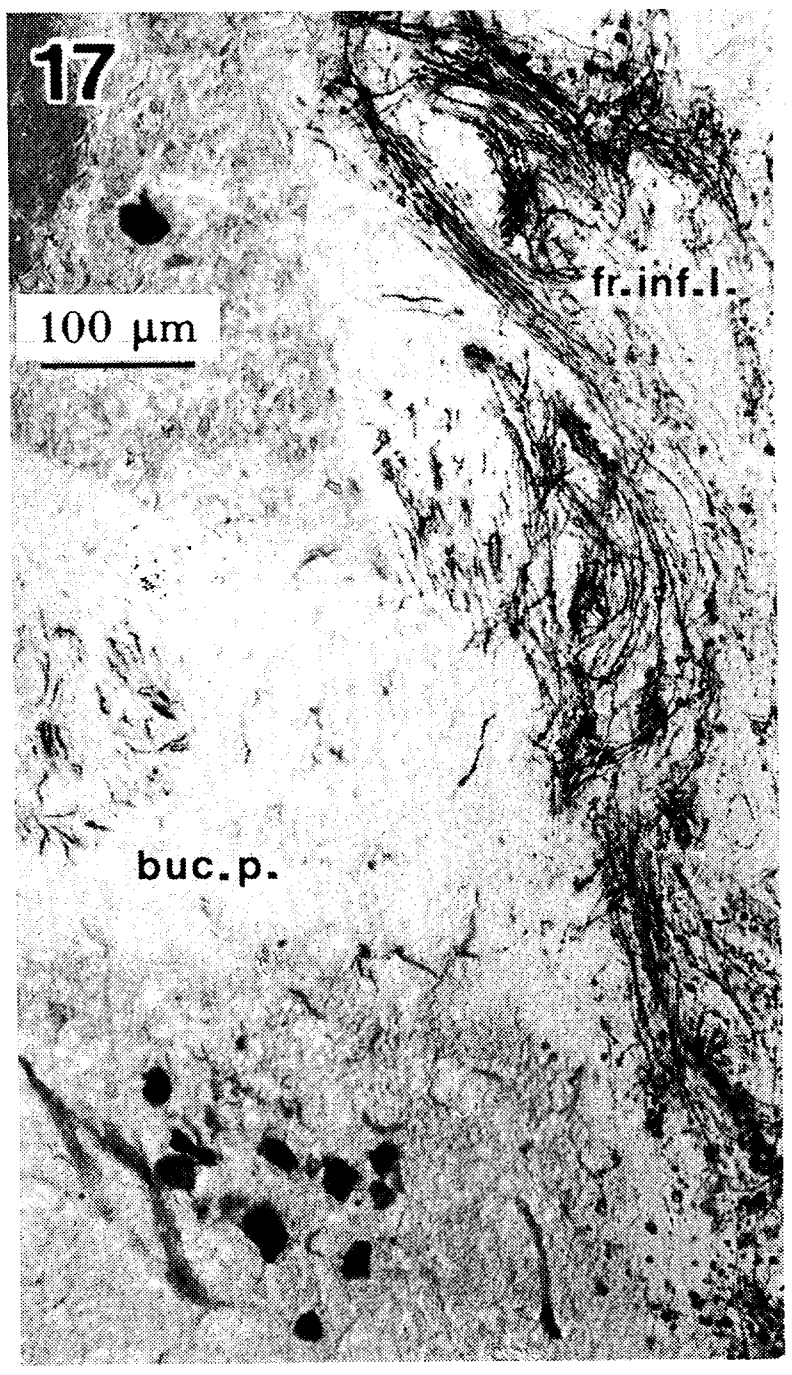

18

Figures 12–18. For description see opposite plate 4.

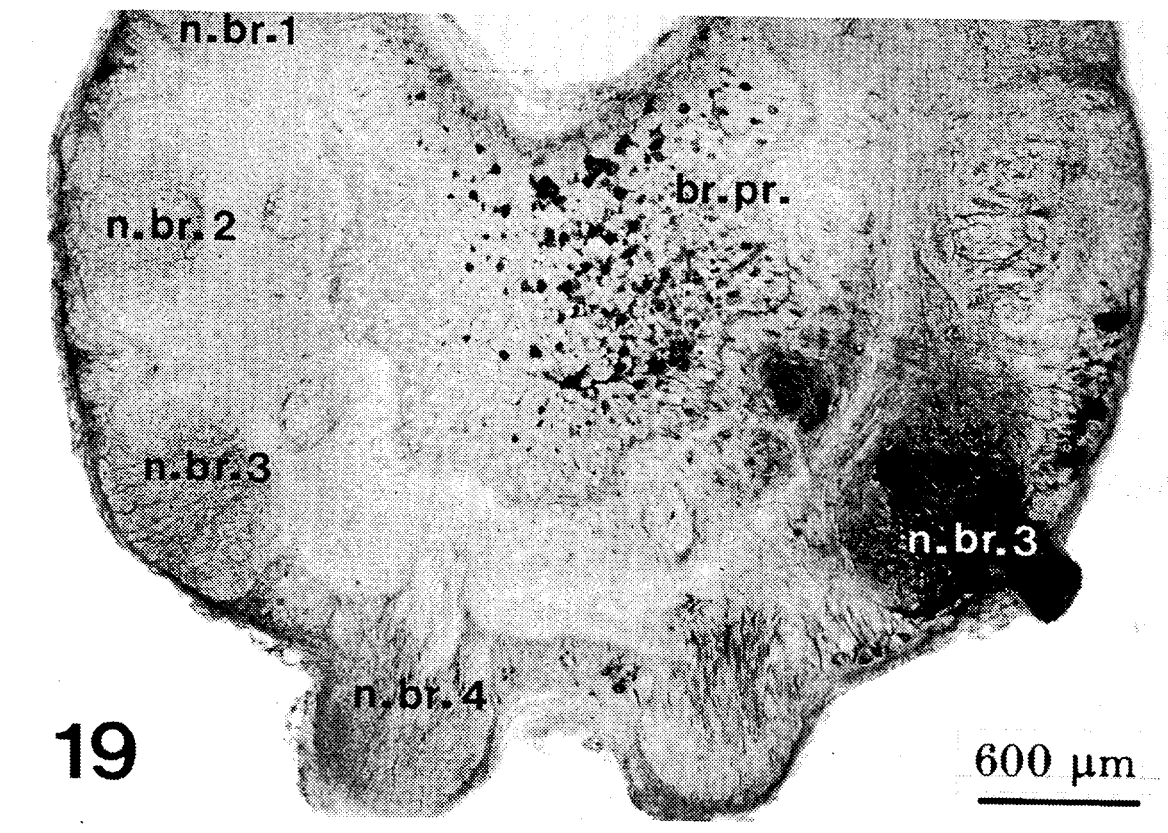

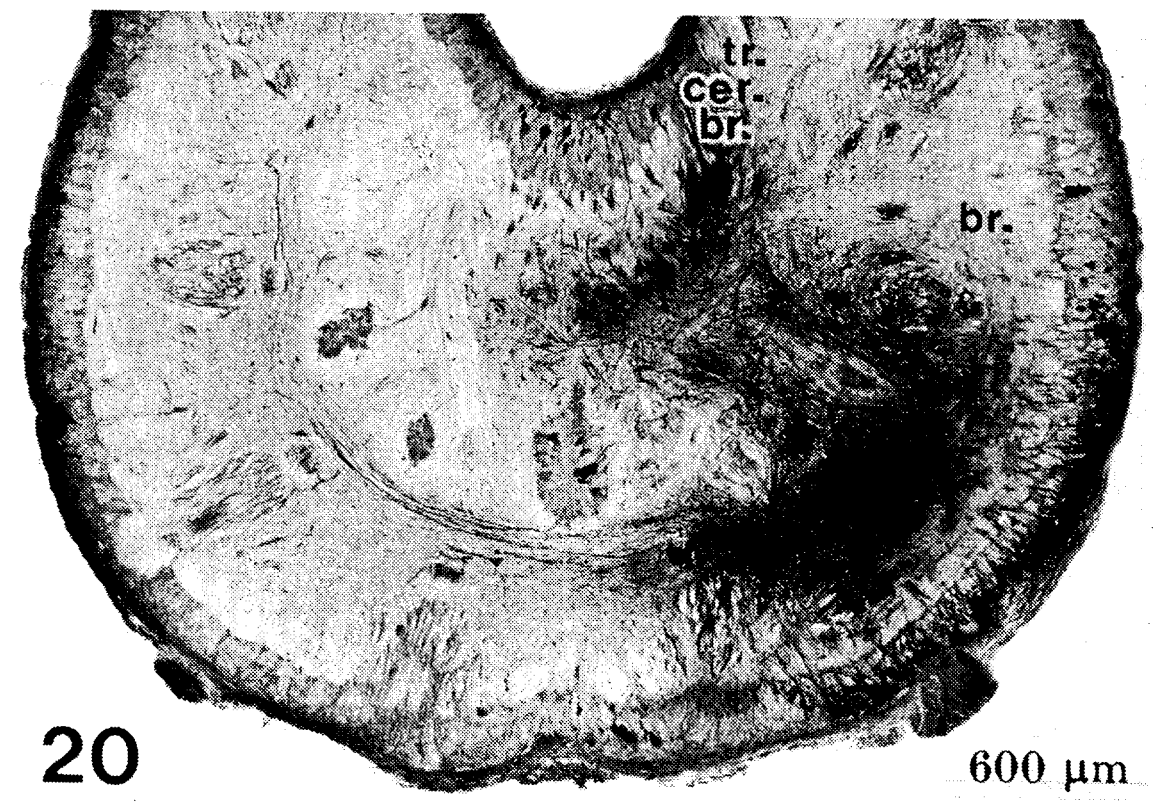

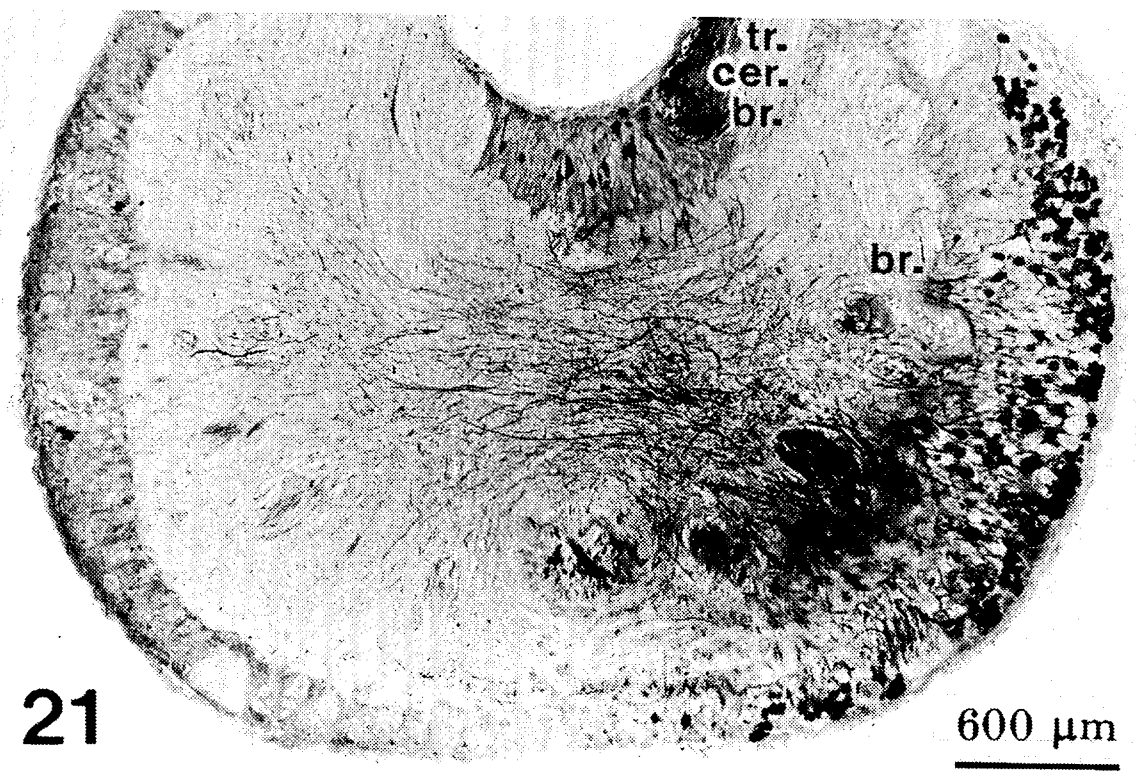

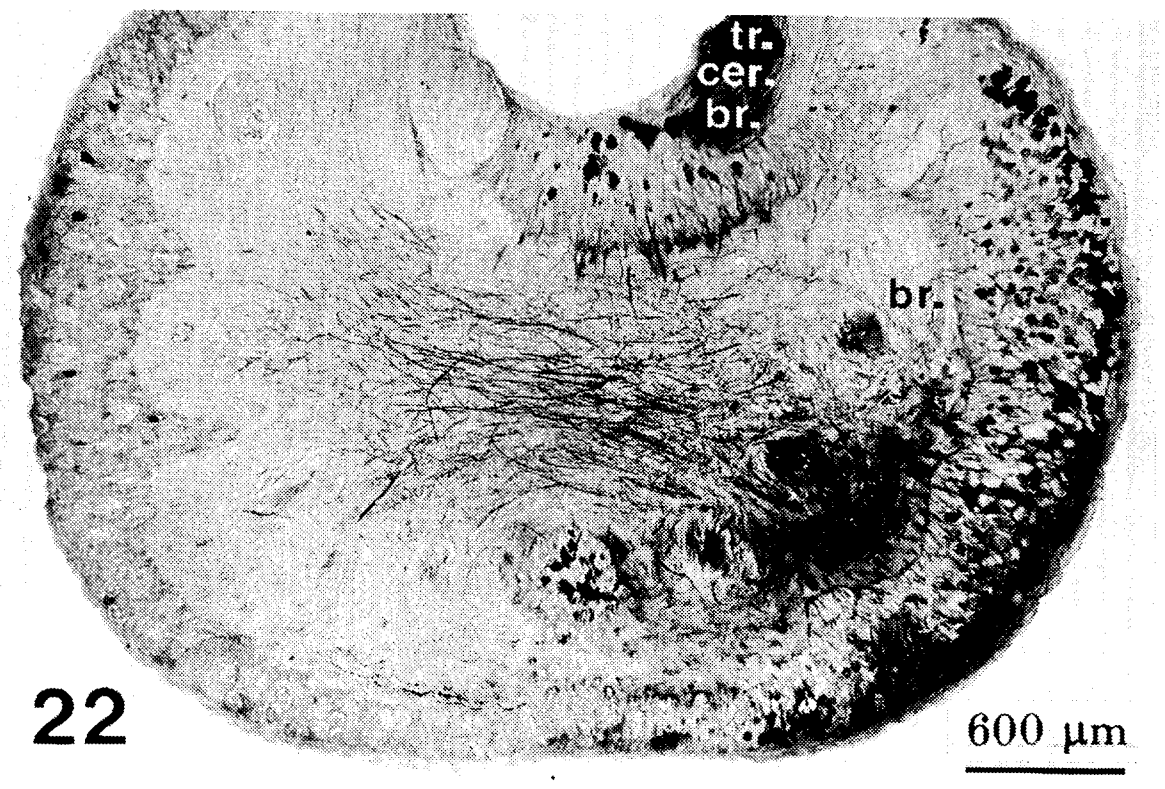

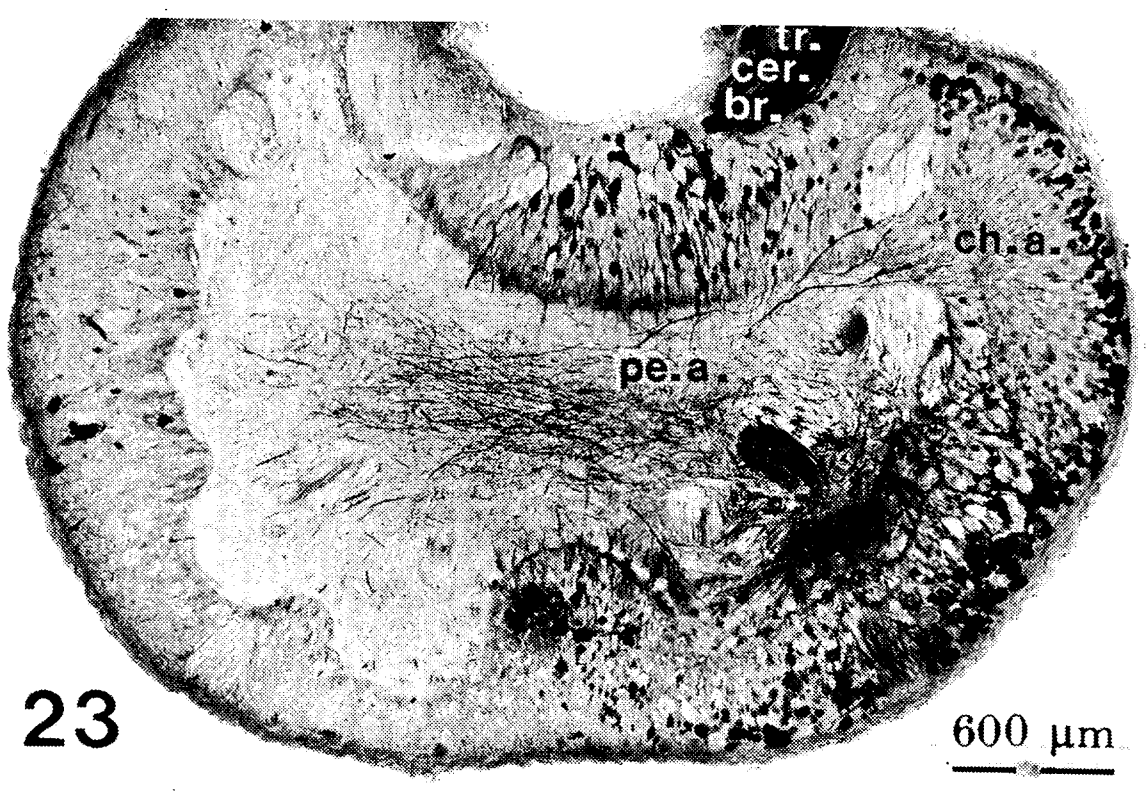

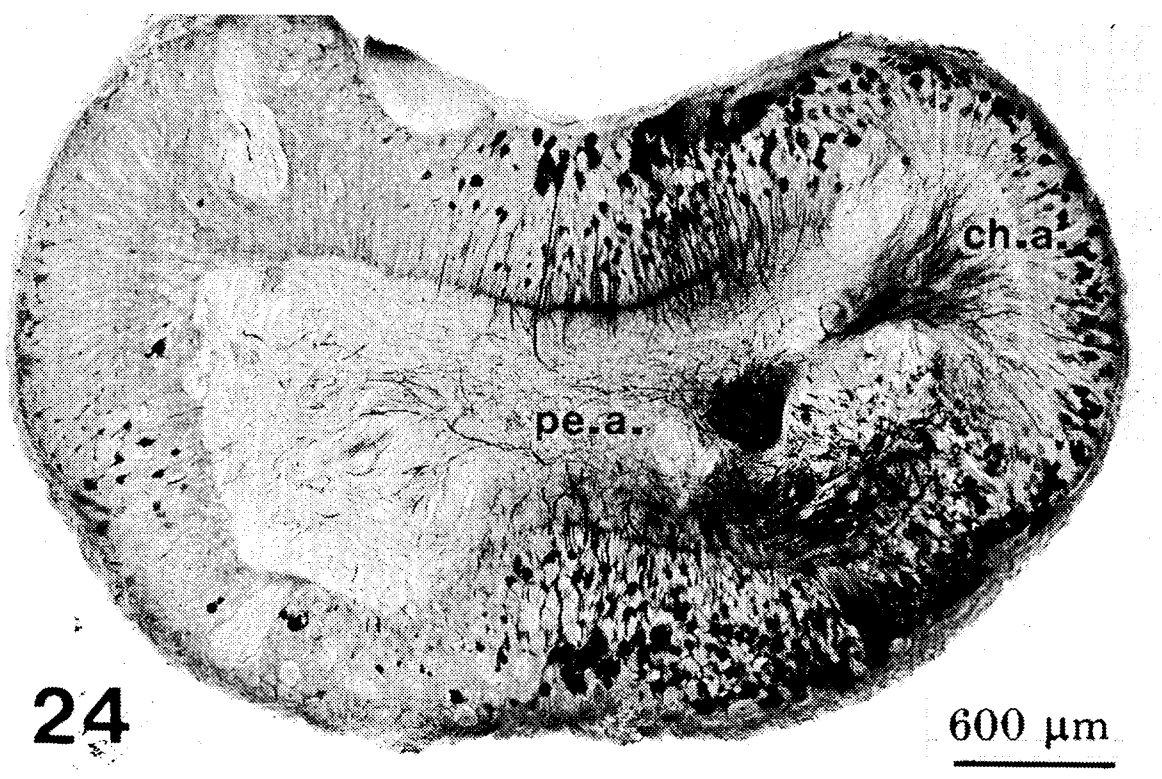

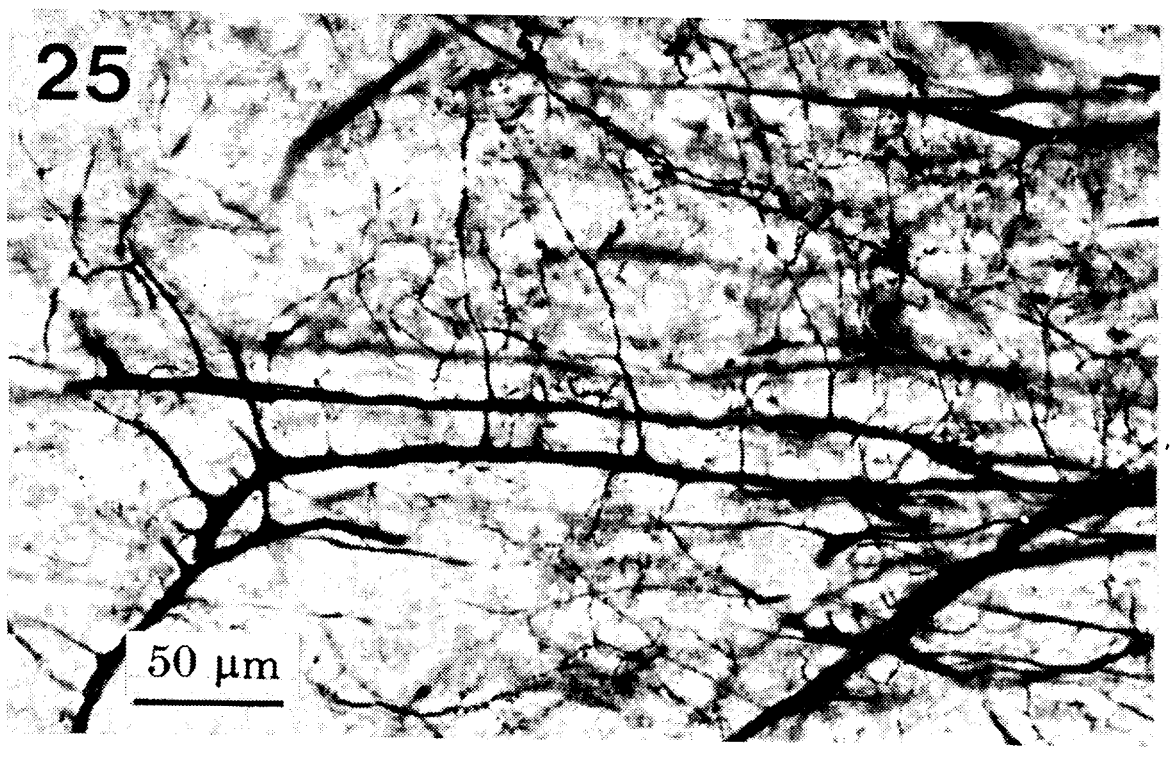

FIGURES 19–26. For description see opposite.

DESCRIPTION OF PLATE 3

Sagittal (figures 12, 13, 15, 16 and 18) and transverse sections (figures 14 and 17) of the supraoesophageal lobes of the *Octopus* brain after centripetal cobalt filling of the third brachial nerve.

FIGURES 12, 13 AND 15. Somata and afferent fibres in the superior and posterior buccal lobes, and afferent fibres in the inferior frontal lobe. Some fibres can be seen in figure 13 proceeding in the interfrontal tract from the back of the posterior buccal to the superior frontal lobe.

FIGURES 14 AND 17. Somata along the floor of the posterior buccal lobe in the region close to the subfrontal lobe, and the network of afferent fibres in the lateral inferior frontal lobe.

FIGURES 16 AND 18. Fibres proceeding in the cerebral tract through the posterior buccal to the subvertical lobe.

DESCRIPTION OF PLATE 4

Transverse (figures 19–24 and 26) and sagittal sections (figure 25) of the anterior suboesophageal lobes of the *Octopus* brain after centripetal cobalt filling of the third brachial nerve.

FIGURE 19. Section of the prebrachial lobe showing somata and the division of the fibres of the third brachial nerve into a large lateral and smaller medial bundle.

FIGURE 20. Afferent fibres in the brachial lobe, some of which cross in a bundle to the contralateral side. The medial bundle of the brachial nerve can be seen proceeding to the cerebrobrachial tract (see also figures 21–23).

FIGURES 21 AND 22. Somata in the ipsilateral and a few in the contralateral brachial lobes, and the network of afferent fibres throughout the neuropil of the brachial lobe.

FIGURES 23 AND 24. Somata dorsally and ventrally in the anterior pedal lobe and in the outer layer of the anterior chromatophore lobe. A few somata are seen in the anterior chromatophore lobe of the contralateral side

FIGURE 25. Trunks of somata of the brachial lobe showing many collateral fibres.

FIGURE 26. Network of afferent fibres in the brachial lobe.

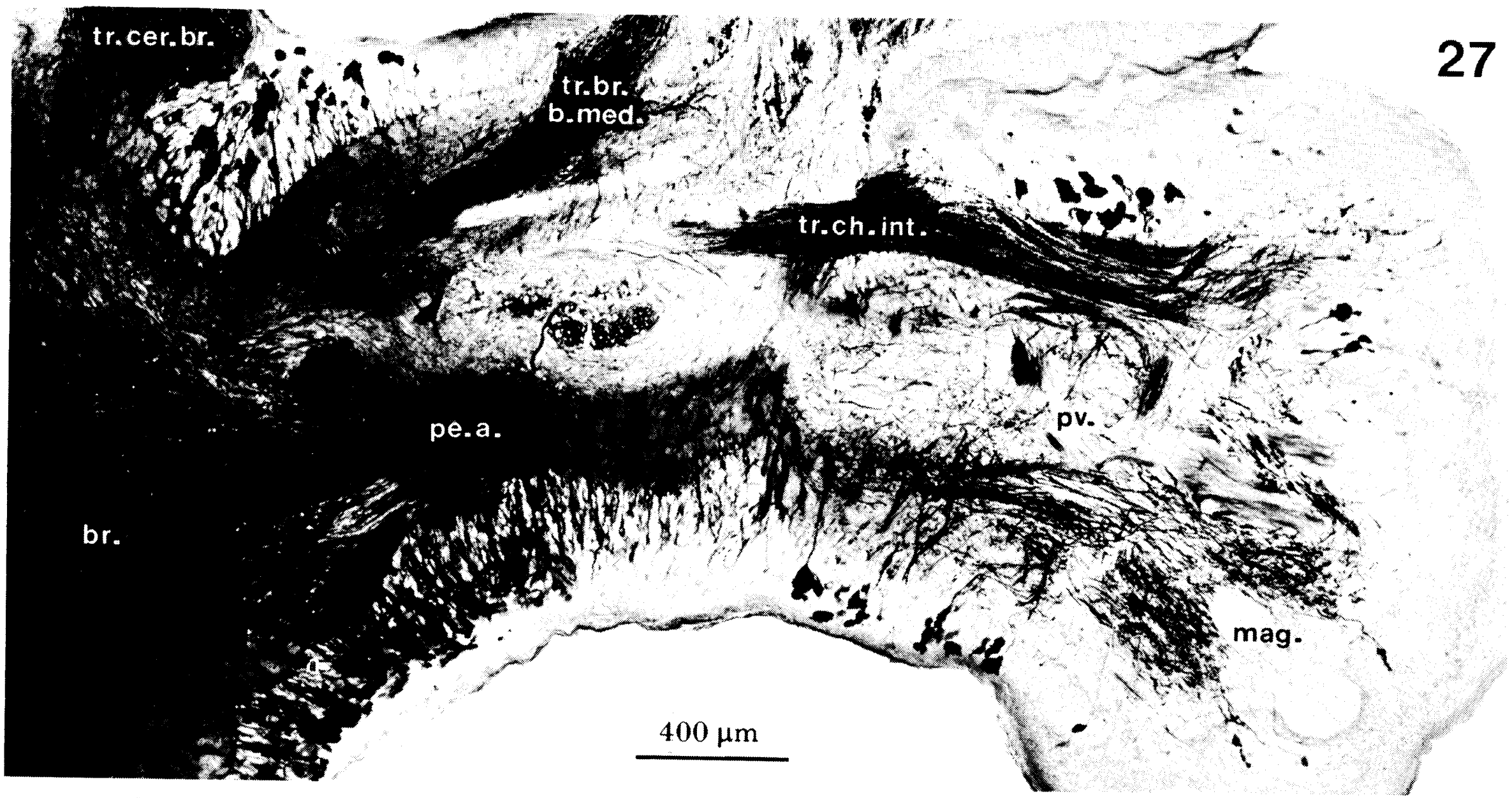

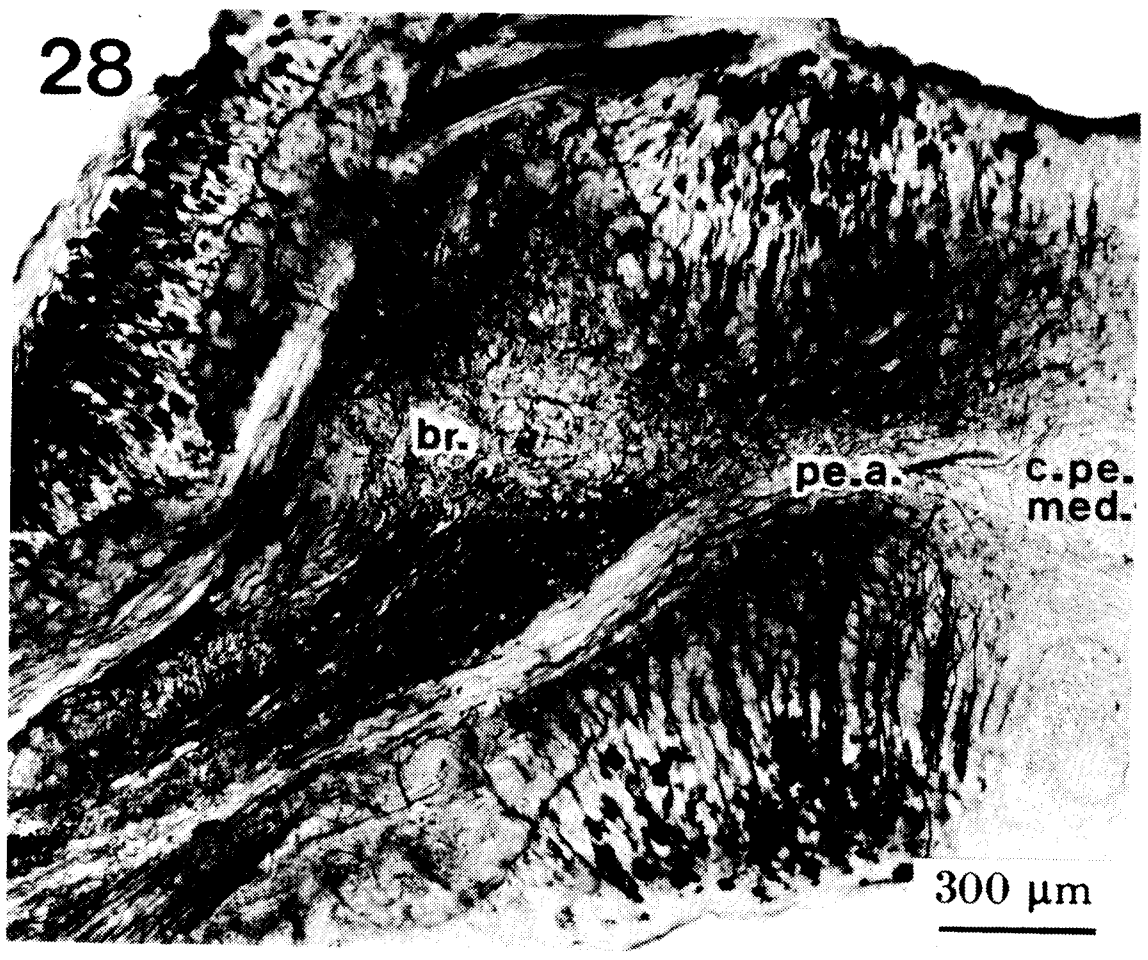

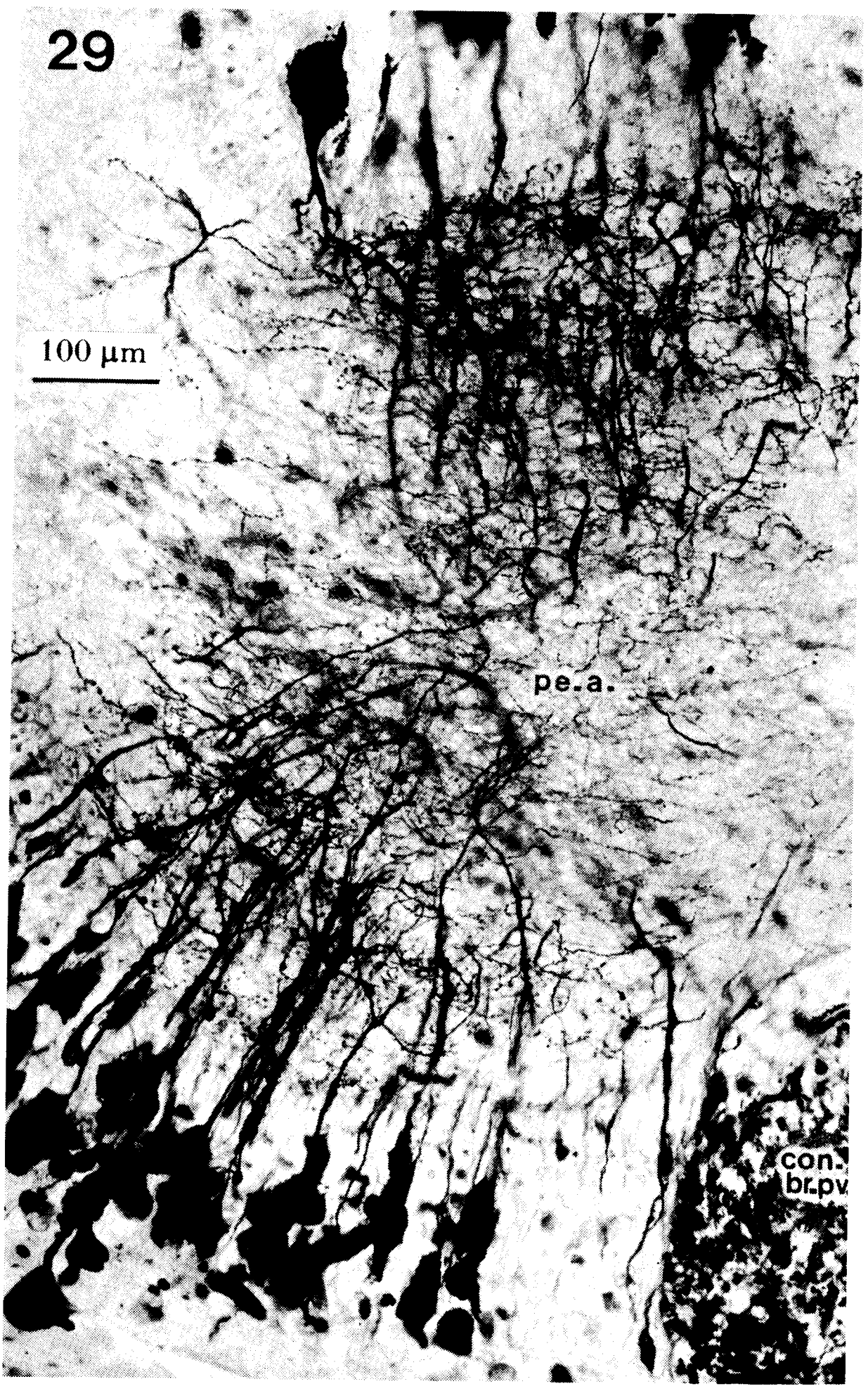

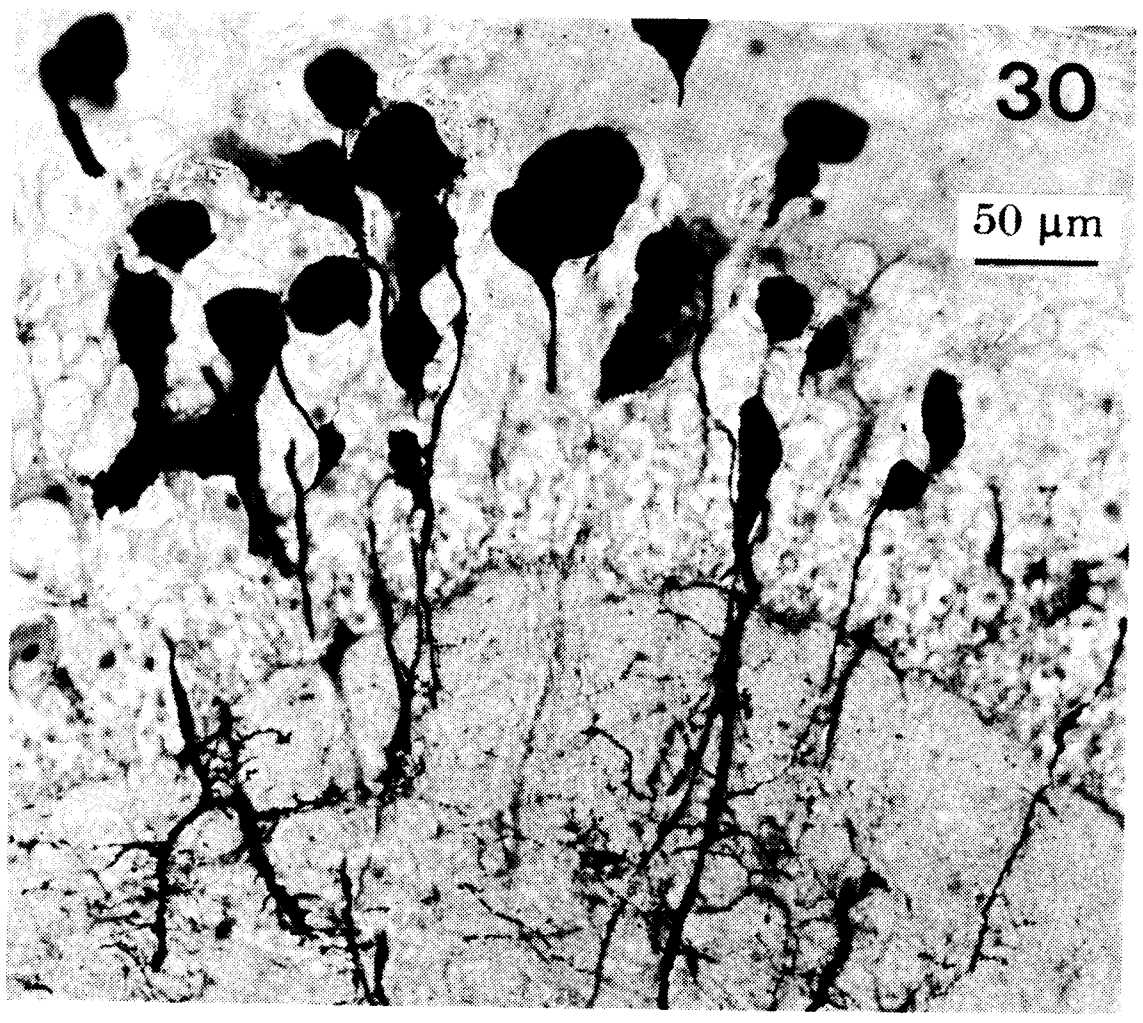

FIGURES 27–30. For description see opposite.

DESCRIPTION OF PLATE 5

Sagittal (figure 27 and 28) and transverse sections (figures 29 and 30) of the suboesophageal lobes of the *Octopus* brain after centripetal cobalt filling of the third brachial nerve.

FIGURE 27. Somata in the brachial, anterior pedal and palliovisceral lobes, and fibres in the cerebrobrachial, brachial to median basal, and interchromatophore lobe tracts.

FIGURE 28. Somata in the medial part of the prebrachial lobe, and dorsally and ventrally in the anterior pedal lobe.

FIGURES 29 AND 30. Somata in the anterior pedal lobe; some of their trunks show fine collateral fibres.

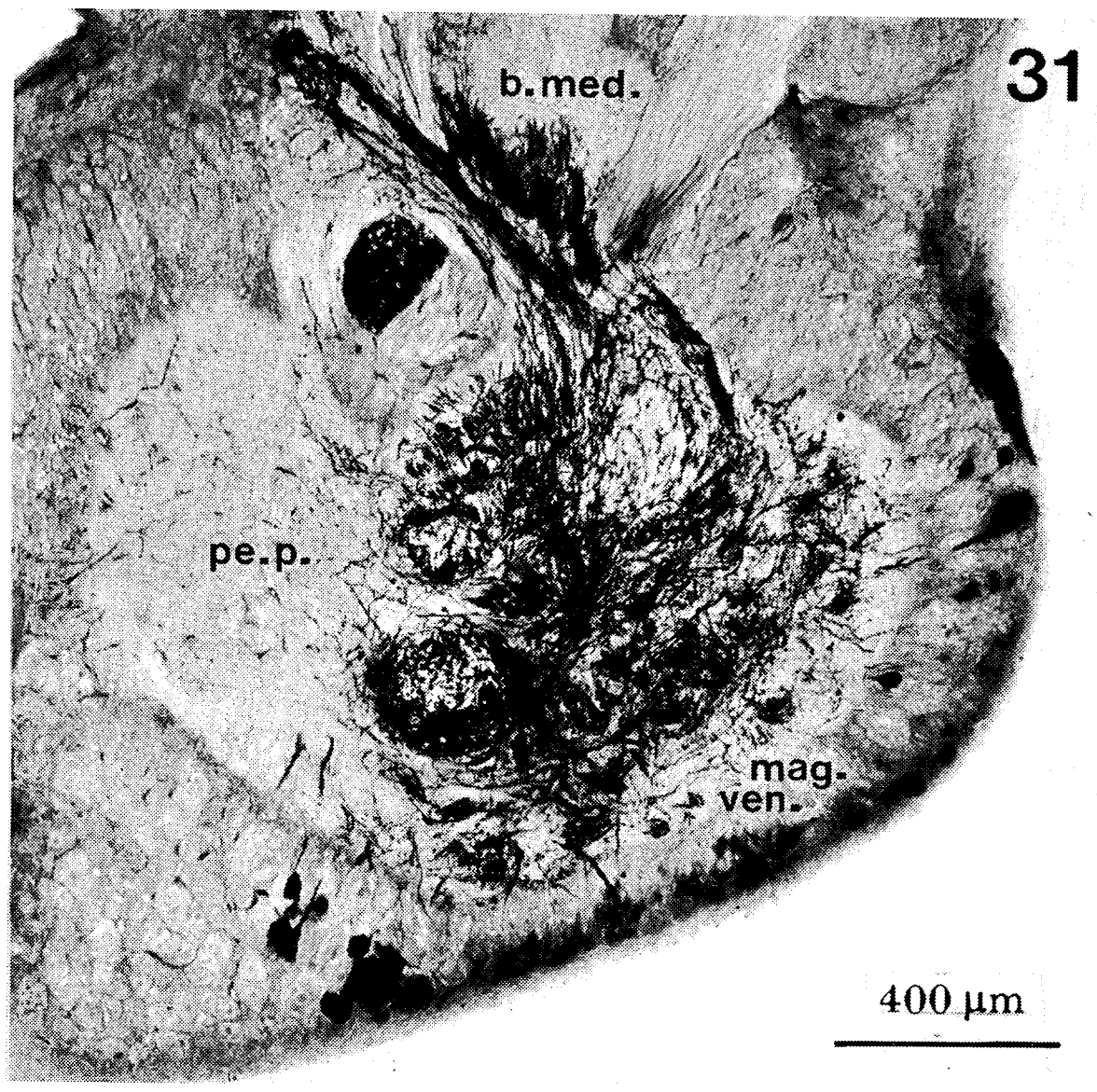
31

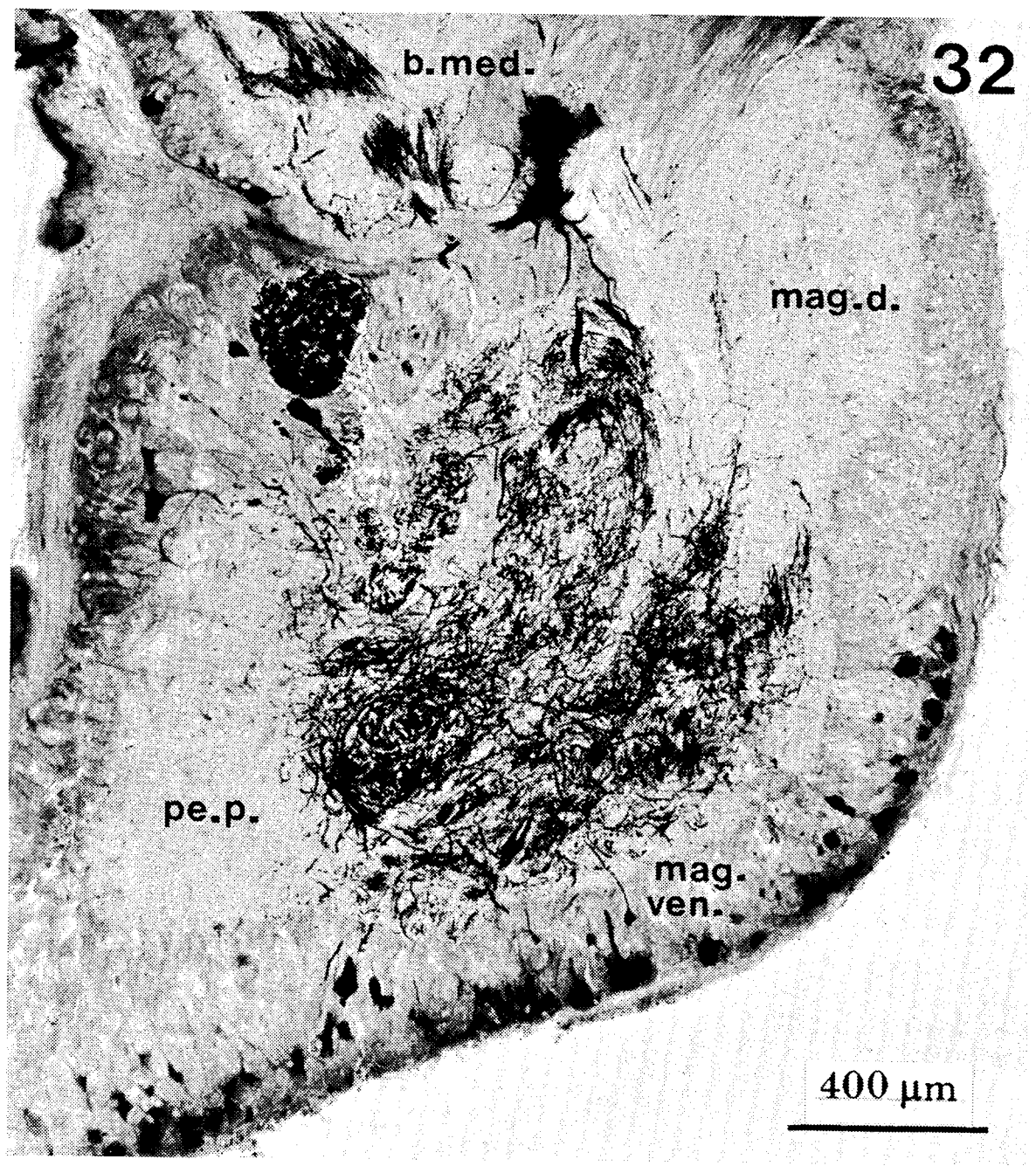
32

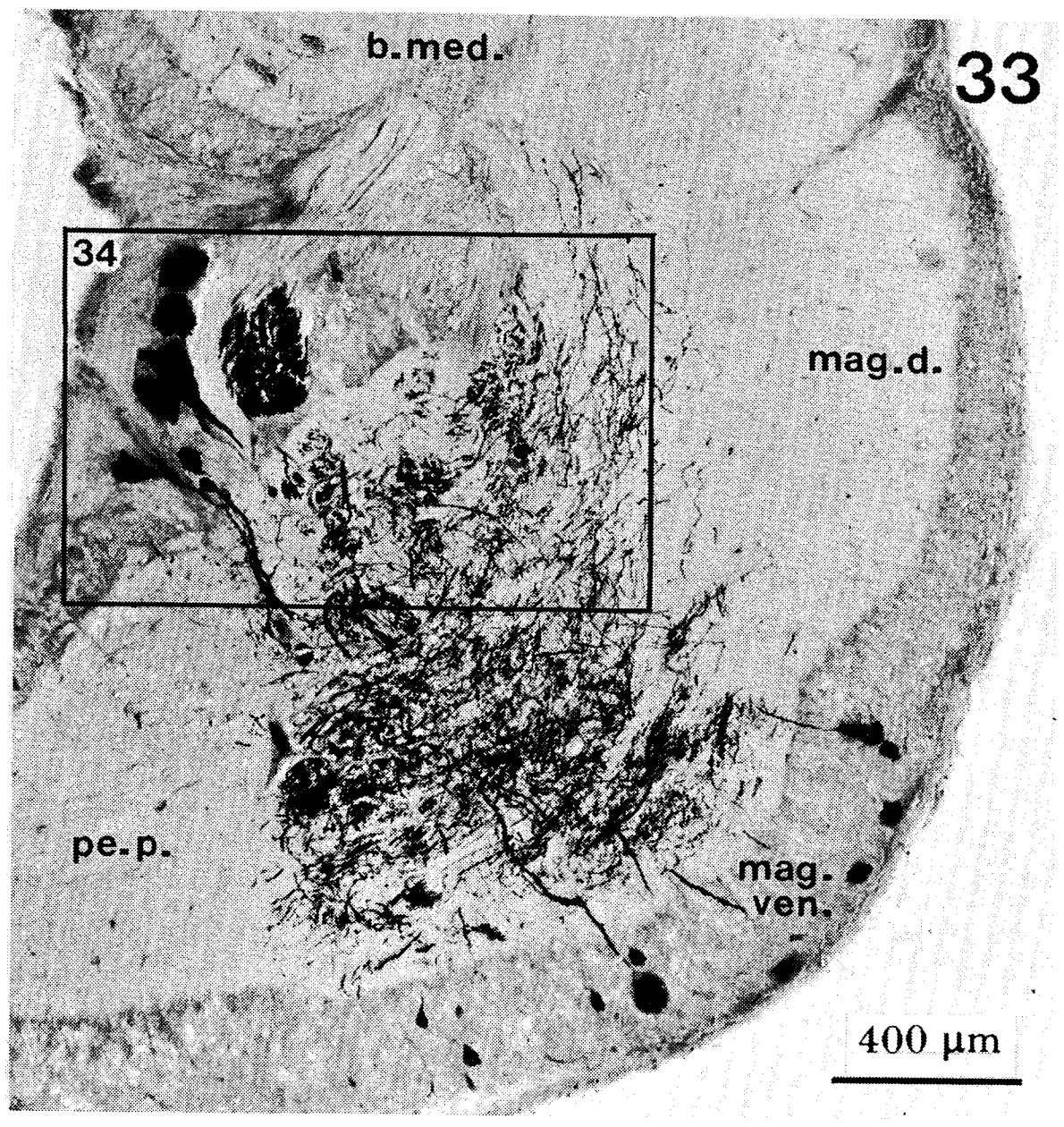
33

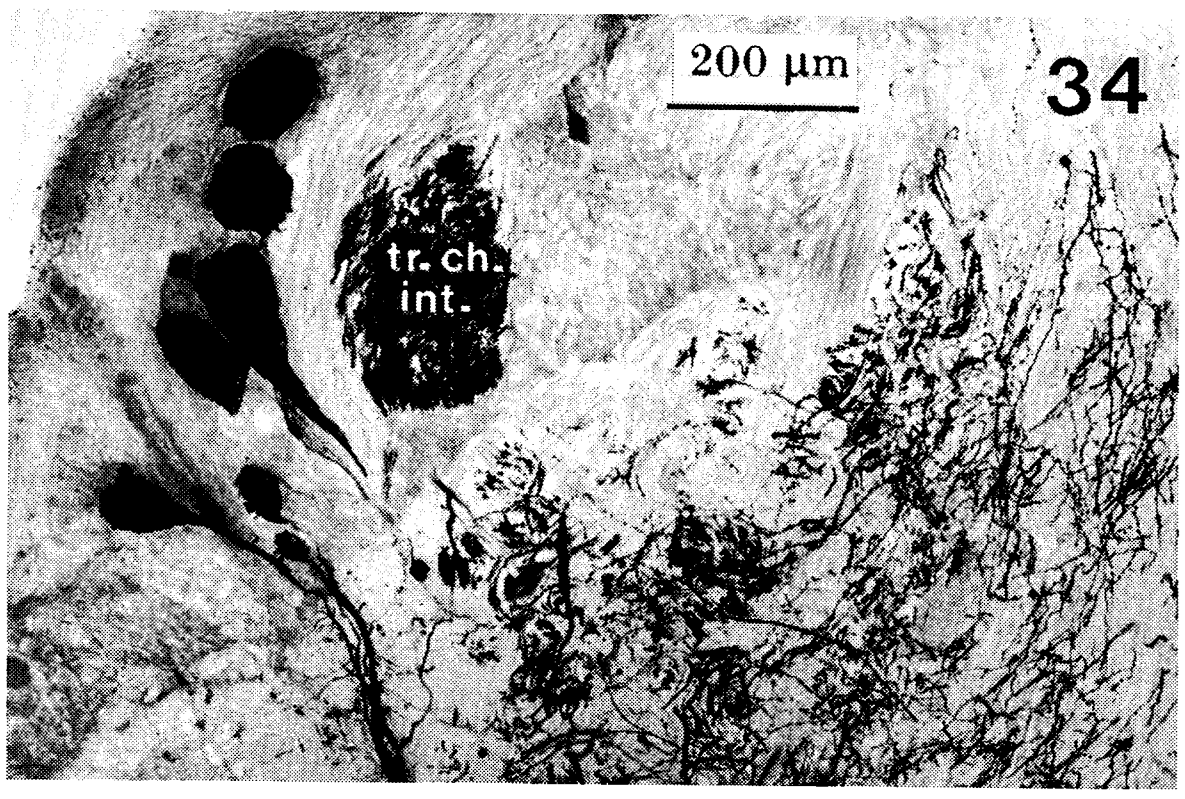
34

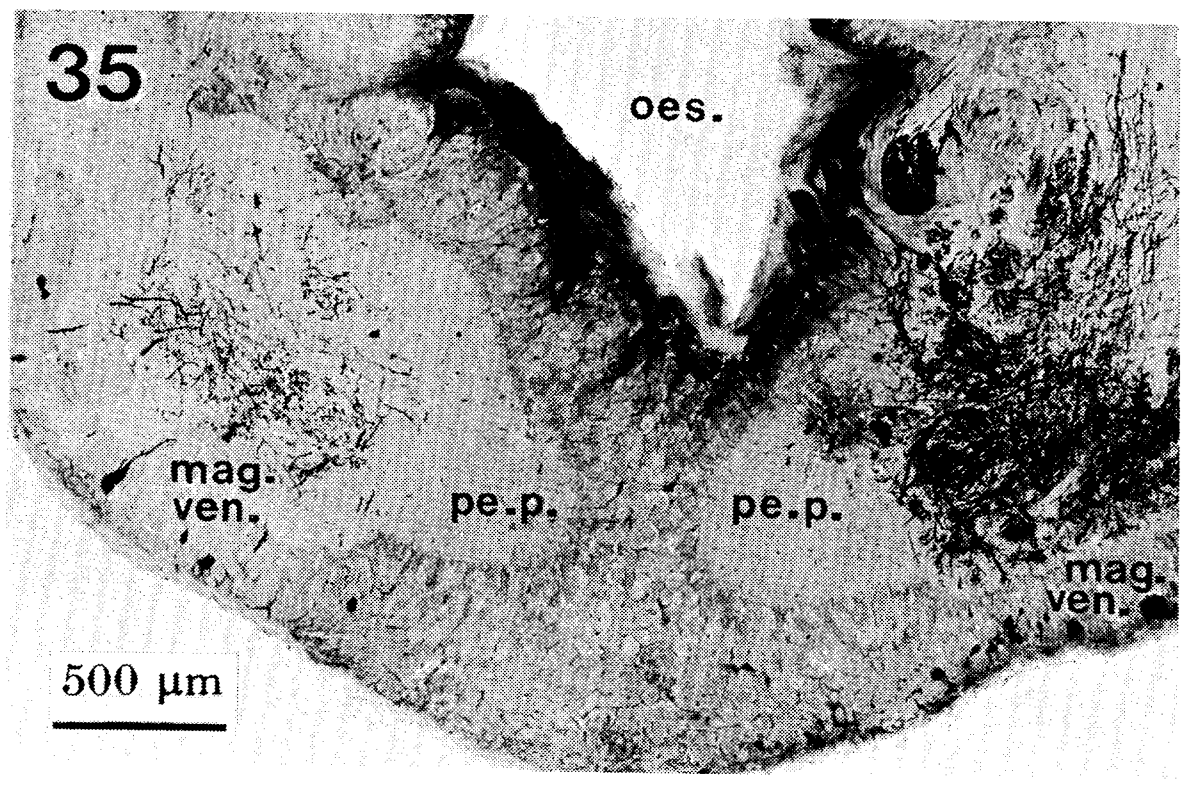
35

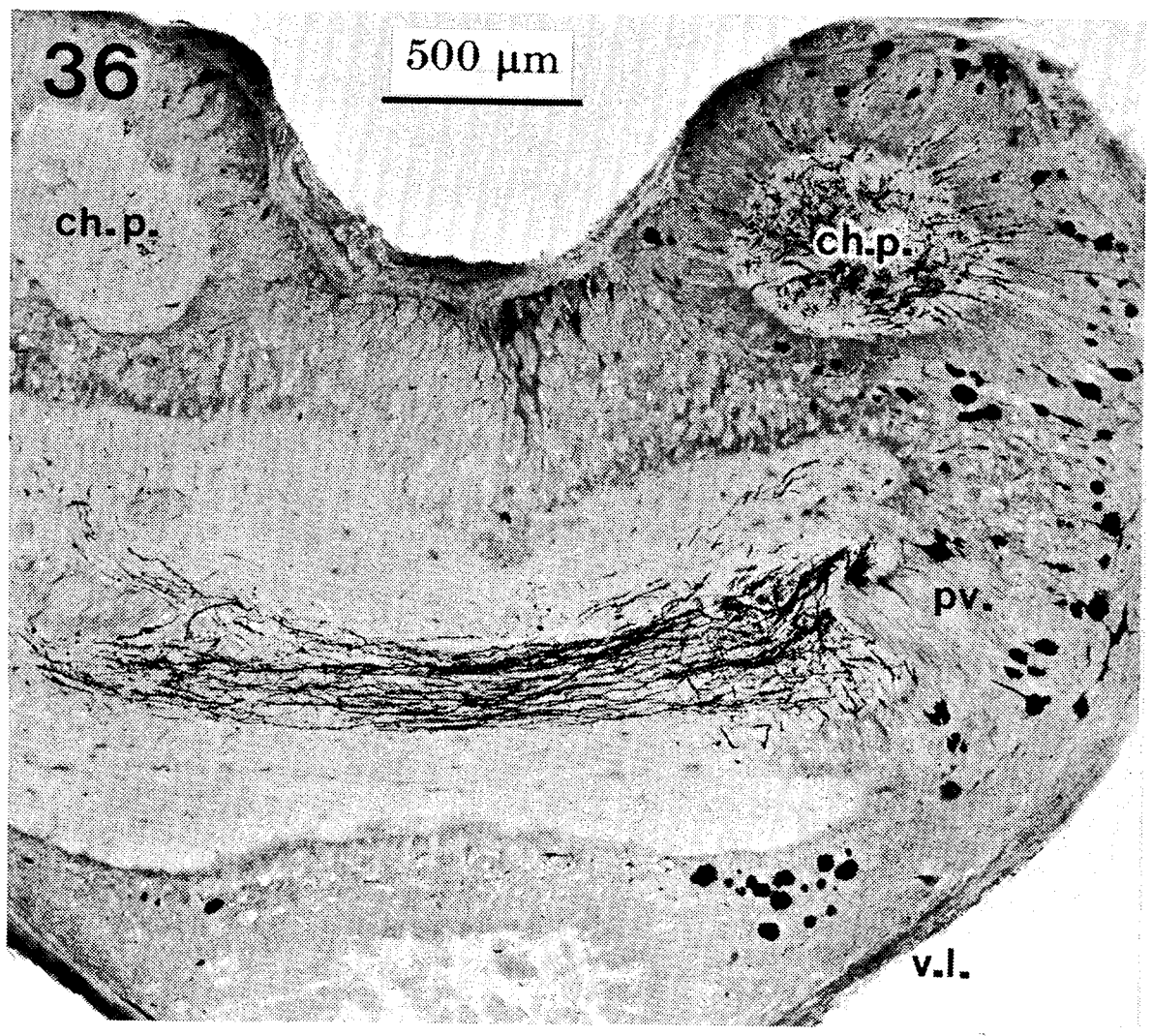
36

FIGURES 31–36. For description see opposite.

3.1.2. *Suboesophageal lobes*

The pattern of distribution of filled fibres and somata can be well seen in the cleared brain before sectioning (figure 1). Many somata are filled in the anterior suboesophageal mass of the brain and in the anterior chromatophore lobe, both dorsally and ventrally. Many fibres are seen in the ipsilateral brachiopalliovisceral lobe connective and some in that of the other side (figure 4). Some fibres pass up to the median basal lobe. Others end in the palliovisceral and magnocellular lobes and there are somata filled here too (figures 1–3).

The detailed distribution of the filled fibres and somata can be followed on the serial transverse and sagittal sections. Shortly after entry, the brachial nerve divides into smaller medial and larger lateral divisions (figures 19 and 20, plate 4). The medial bundle proceeds largely to the cerebrobrachial tract (figures 20–23) and to the suprabrachial commissure. Many fibres of the lateral bundle spread throughout the prebrachial lobe and are clearly afferents (figures 20 and 26). They mainly remain within the territory of the nerve that has been filled but pass also to other parts of the lobe and some cross to the other side (figures 20–23). Some filled fibres are seen in the roots of other brachial nerves, including the first brachial.

Many somata are filled in the ipsilateral prebrachial and brachial lobes, mainly laterally in the region of entry of the nerve but some medially at the front end (figures 19 and 20). The somata are all large, lying in the outer layers. Their trunks sometimes show many collateral fibres (figure 25). None of the numerous small somata in the inner layers are filled. Only very few somata are filled on the opposite side (figures 3, 4, 22 and 23). At the back of the brachial lobe many somata are filled in the lateral wall and afferent fibres spread throughout the neuropil and across to the other side (figure 21).

At the front of the pedal lobe many somata are filled in the dorsal and ventral anterior chromatophore lobes. They are mainly large and lie in the outer part of the perikaryal layer (figures 23 and 24). Some filled fibres pass back into the interchromatophore lobe tract (figures 31–35, plate 6) and can be followed to the posterior chromatophore lobe, where many filled fibres can be seen in the neuropil. There are also some filled somata in that lobe (figure 36). Therefore, there must be motoneurons for chromatophores of the arms in both the anterior and the posterior chromatophore lobes. From both the anterior and posterior chromatophore lobes some fibres can be followed through the chromatophore commissures to the contralateral side, but only very few filled somata are seen in these contralateral chromatophore lobes (figures 24 and 36). Some very fine contralateral fibres could not be followed to somata; as for the pallial nerve (see §3.2.2.2.), these are presumed to be either axons or dendritic collaterals of the ipsilateral chromatophore motoneurons.

Description of plate 6

Transverse section of the posterior suboesophageal lobes of the *Octopus* brain after centripetal cobalt filling of the third brachial nerve.

Figures 31 and 32. Somata and afferent fibres in the ventral magnocellular lobe. Some of the afferent fibres proceed upwards to the median basal lobe.

Figures 33 and 34. Somata and afferent fibres in the magnocellular lobe, with some very large somata in its dorsal wall close to the oesophagus. Many fibres are seen in the interchromatophore lobe tract.

Figure 35. Somata and afferent fibres in the ipsilateral and some in the contralateral ventral magnocellular lobe.

Figure 36. Somata in the posterior chromatophore and palliovisceral lobes. Many fibres are seen crossing in a commissure at the back of the palliovisceral lobe.

Many somata are filled in the anterior pedal lobe, both dorsally and ventrally. They include large and medium but no small cells (figures 27–30, plate 5). It is striking that in both the chromatophore and pedal lobes there are few or no afferent fibres filled in the neuropil, compared with the brachial lobes.

Proceeding backwards in the pedal lobe the number of filled somata and fibres diminishes rapidly (figure 28). None are present in the central part of the lobe nor in the posterior pedal or in the anterior or posterior lateral pedal lobes. At this level the only signs of filling are in fibres of the brachiopalliovisceral and interchromatophore lobe connectives. There are a few fibres also in the contralateral brachiopalliovisceral lobe connective.

Large filled somata are numerous all round the dorsal and ventral surfaces of the ventral magnocellular lobe (figures 1, 31–33 and 35). At this level many fibres emerge from the brachiopalliovisceral connective and spread throughout the neuropil (figure 31). Many are obviously afferents. This is therefore a region operating some reflex control of movements of the arms, perhaps as part of avoiding reactions (Boycott 1961).

Some fibres proceed upwards to spread out at the base of the median basal lobe, where some somata are also filled (figures 31 and 32). A few fibres also emerge from the contralateral brachiopalliovisceral lobe connective and spread out in the neuropil of the ventral magnocellular lobe and a few somata are filled here (figure 35). No filled fibres were seen proceeding to the brachio-optic tract.

Many somata are filled further back in the ipsilateral magnocellular lobe, including some very large ones in its dorsal wall (figures 33 and 34). These are some of the largest nerve cells in *Octopus*. They are oval in form, up to 180 μm × 80 μm. The neuropil around their dendrites has many fine fibres, presumably afferents from the arms. These somata can already be seen around the magnocellular lobe in the cleared brain before sectioning.

Somata and fibres in the neuropil are also filled in the palliovisceral lobe, including its lateral wall and in the region of small cells presumed to be vasomotor (figure 36). Many filled fibres of the brachiopalliovisceral lobe connective cross in a commissure at the back of the palliovisceral lobe and end in the contralateral lobe (figure 36). These fibres are probably largely afferents but there are a few somata filled on the contralateral side (figures 3 and 36). The filled fibres of the contralateral brachiopalliovisceral lobe connective also end in the contralateral palliovisceral lobe. They all are presumed to be afferents. Thus after filling of a brachial nerve the contralateral palliovisceral lobe gets input from afferent fibres of both the ipsi- and contralateral brachiopalliovisceral lobe connectives.

3.2. *Centripetal cobalt filling of the pallial nerve*

3.2.1. *Peripheral distribution of the pallial nerve*

The pallial nerve is mainly composed of fibres controlling the muscles and skin of the mantle. It also contains motor fibres for the retractor muscles in the capsule of the digestive gland. The fibres for the control of the mantle muscles run to the stellate ganglion and synapse there. For this reason the pallial nerve is often called the mantle connective. The fibres for the chromatophores and muscles of the skin pass through the stellate ganglion without synapsing there (Young 1971).

The pallial nerve contains three main groups of fibres (Young 1971). One group has 3200 fibres of 2–16 μm. About 600 of these are between 6 and 16 μm and probably pass to the retractor muscles. The remainder end in the stellate ganglion. A second group contains 2300 fibres less than 4 μm and these probably innervate the chromatophores and skin muscles. A third group of fibres less than 2 μm are probably afferents (Young 1971).

3.2.2. *Central distribution of the pallial nerve*

3.2.2.1. *Whole mount of the brain.* The distribution of filled fibres and somata within the brain is well seen in a lateral view (figure 37, plate 7). The palliovisceral lobe is well filled by a network of fine fibres (figure 37; figure 40, plate 8), and somata are seen in its dorsal and ventral walls. Some of the fine fibres pass through the palliovisceral commissure to the contralateral side (figure 40).

Somata are also seen in the posterior chromatophore lobes (figures 37 and 39). There is some filling of the magnocellular lobe but little is seen in the ventral part of the posterior suboesophageal lobes from which the visceral nerves arise.

Fibres are filled in the interchromatophore lobe tract (figures 37 and 39) and some somata are seen in the anterior chromatophore lobe where they are arranged anteriorly and posteriorly in two small bands (figure 37). Fibres are also filled in the brachiopalliovisceral lobe connective (figures 37 and 40). No other filled somata can be seen in the anterior or middle suboesophageal lobes or in the supraoesophageal lobes, but a bundle of fibres runs to the median basal lobe (figures 37 and 39).

3.2.2.2. *Sections of the brain.* The pallial nerve passes to the centre of the palliovisceral lobe and there it divides into a series of branches proceeding to five destinations.

(i) Fibres to the chromatophore lobes. A very large branch turns dorsally into the posterior chromatophore lobe (figure 41; figure 48, plate 9). Before entering the lobe it sends a large branch forwards into the interchromatophore lobe tract (figures 43 and 48). The fibres form a plexus at the base of the posterior chromatophore lobe and pass directly across the neuropil to the origin of their somata, many of which are filled (figures 38, 50, 51; figures 55, 56 and 58, plate 10). The trunks of the cells show collaterals with swellings such as have been seen in Golgi and Cajal silver preparations (Young 1971). The branch to the anterior chromatophore lobe contains many large fibres (figure 43). They interweave as they enter the lobe and proceed to the somata filled in small bands anteriorly and posteriorly (figures 38, 42 and 45). From both the anterior and posterior chromatophore lobes a few fibres were seen crossing through the chromatophore commissures to the contralateral side (figure 44), but no somata were filled contralaterally in either of the chromatophore lobes. The nature of these fibres is difficult to decipher because there is no evidence for afferent fibres to the chromatophore lobes from the pallial nerve; they are possibly axons or dendritic collaterals of the ipsilateral chromatophore motoneurons.

(ii) Fibres to the palliovisceral lobe. A large set of fibres leaves the pallial nerve root dorsally and passes to filled somata all along the dorsal wall of the palliovisceral lobe (figures 46 and 47). The fibres give collaterals in the neuropil but they do not carry large swellings such as are seen in the chromatophore lobes. Many fine fibres leave the pallial nerve at this level and branch and form a network of interweaving fibres at the centre of the dorsal part of the lobe (figure 47). Some of these fibres cross through the palliovisceral commissure to end in the same region of the opposite side (figure 46), but no somata are filled in any of the contralateral posterior suboesophageal lobes. Other fibres from the pallial nerve pass medially downwards and forwards and numerous somata are filled along the medial ventral surface of the palliovisceral lobe (figures 38, 43 and 48). Fibres from the pallial nerve thus proceed to somata all around the palliovisceral lobe, including its most anterior wall. Here, there is a conspicuous group of small filled somata (figure 49). There are also some very large somata filled in this region, including an outstanding single one near the midline. The visceral and vasomotor lobes at the hind end of the posterior suboesophageal mass of the brain usually show no filled somata even in sections that have been strongly intensified (for example, figure 49). Occasional filled somata near these areas may belong to the magnocellular lobe.

(iii) Fibres to the median basal lobe. A compact bundle of fibres passes forwards to the base of the median basal lobe (figure 50). Many of these fibres are small and branch profusely and are presumably afferents (figures 53 and 54). A few of these fibres are large efferents and some of their somata have been filled at the anterior surface of the extreme lower margin of the median basal lobe (figure 51). Some somata are also filled in the posterior cell layer of the lobe (figure 51). The afferent fibres to the median basal lobe are also well seen in the transverse sections (figure 52). They proceed upwards for some distance but none have been followed to the subvertical lobe. Some fibres cross in the suprapedal commissure (figure 53).

(iv) Fibres to the magnocellular lobe. The most lateral bundle of pallial nerve fibres turns sharply downwards towards the magnocellular lobe (figures 38 and 56). This branch contains the largest fibres in the pallial nerve (up to 15 μm in diameter). They send long branches forwards into the neuropil of the palliovisceral lobe, as well as downwards to the magnocellular lobe (figures 56 and 58). The main branches divide into finer ones throughout a large volume of neuropil. It was not possible to follow their main trunks to somata, but presumably they are dendrites of efferent fibres arising from the large somata which occur at intervals along the floor of the ventral magnocellular lobe (figures 52 and 55). The innervation of the magnocellular lobe is difficult to decipher. Its neuropil and connective tissue are often deeply stained, probably by the filling of large blood vessels. Many of the fibres are afferents (figure 57), which divide into fine terminal branches. These continue forwards to the front end of the magnocellular lobe

---

Description of plate 7

Suboesophageal lobes of the *Octopus* brain after centripetal cobalt filling of the pallial nerve.

Figure 37. Whole mount of the brain showing somata in the palliovisceral and ventral magnocellular lobes, and in the anterior and posterior chromatophore lobes. Fibres are seen in the palliovisceral and magnocellular lobes, in the interchromatophore lobe tract, in the brachiopalliovisceral lobe connective, and in a bundle running to the median basal lobe.

Figure 38. Sagittal section of the preparation of figure 37.

Description of plate 8

Whole mounts (figures 39 and 40), sagittal (figures 41, 43 and 45) and transverse sections (figures 42 and 44) of the *Octopus* brain after centripetal cobalt filling of the pallial nerve.

Figure 39. Oblique view from behind of the preparation of figure 37 showing somata in the posterior chromatophore lobe, and fibres running in the interchromatophore lobe tract and to the median basal lobe.

Figure 40. Ventral view of the preparation of figure 37 showing somata in the front of the ventral magnocellular lobe. A network of afferent fibres can be seen in the palliovisceral lobe.

Figure 41. Bundle of fibres running dorsally to the posterior chromatophore lobe.

Figure 42. Somata in the anterior chromatophore lobe. A few fibres can be seen in the brachiopalliovisceral lobe connective.

Figure 43. Fibres in the interchromatophore lobe tract.

Figure 44. Fibres crossing through the anterior chromatophore commissure to the contralateral side.

Figure 45. Somata in the anterior chromatophore lobe.

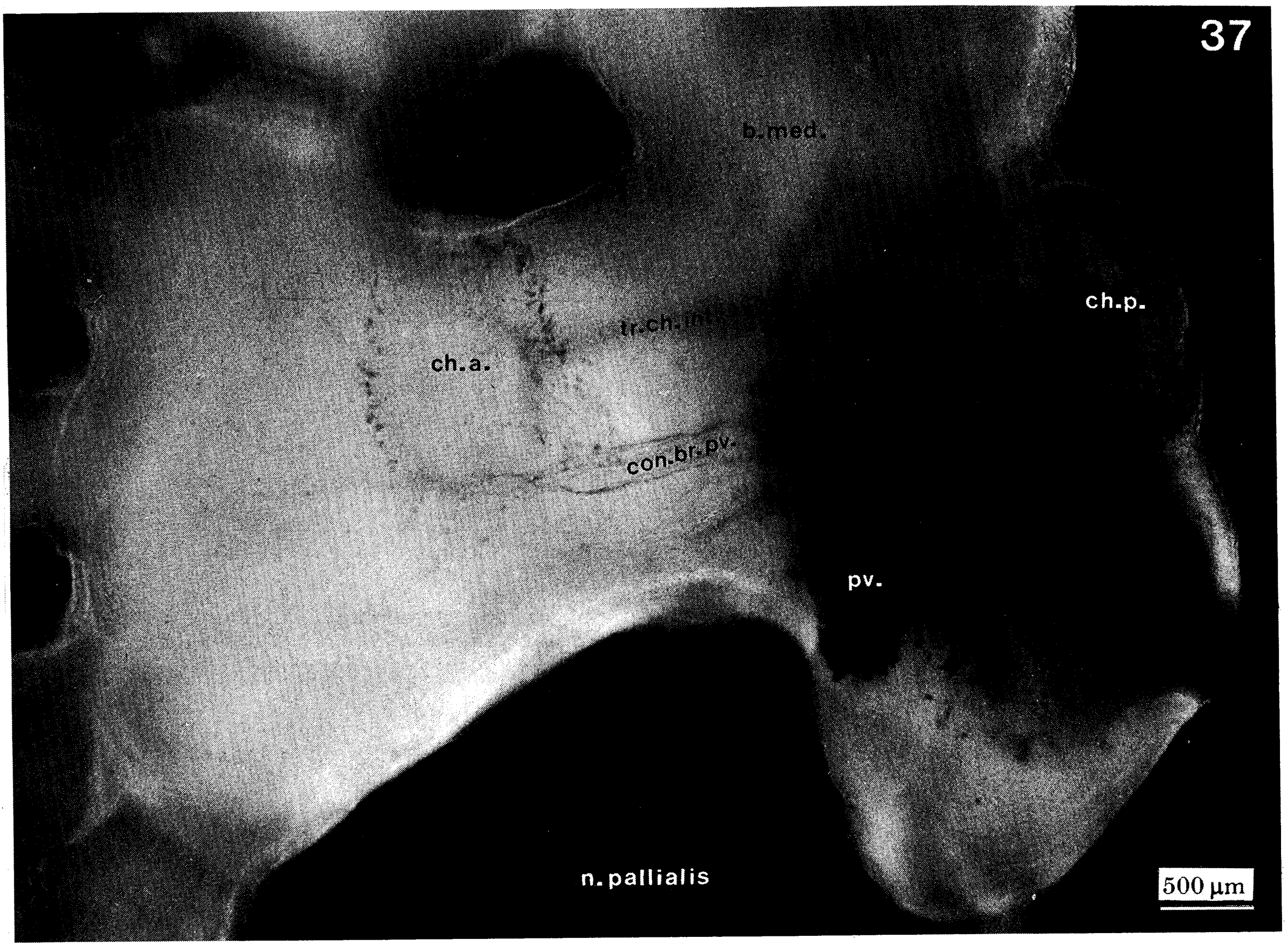

38

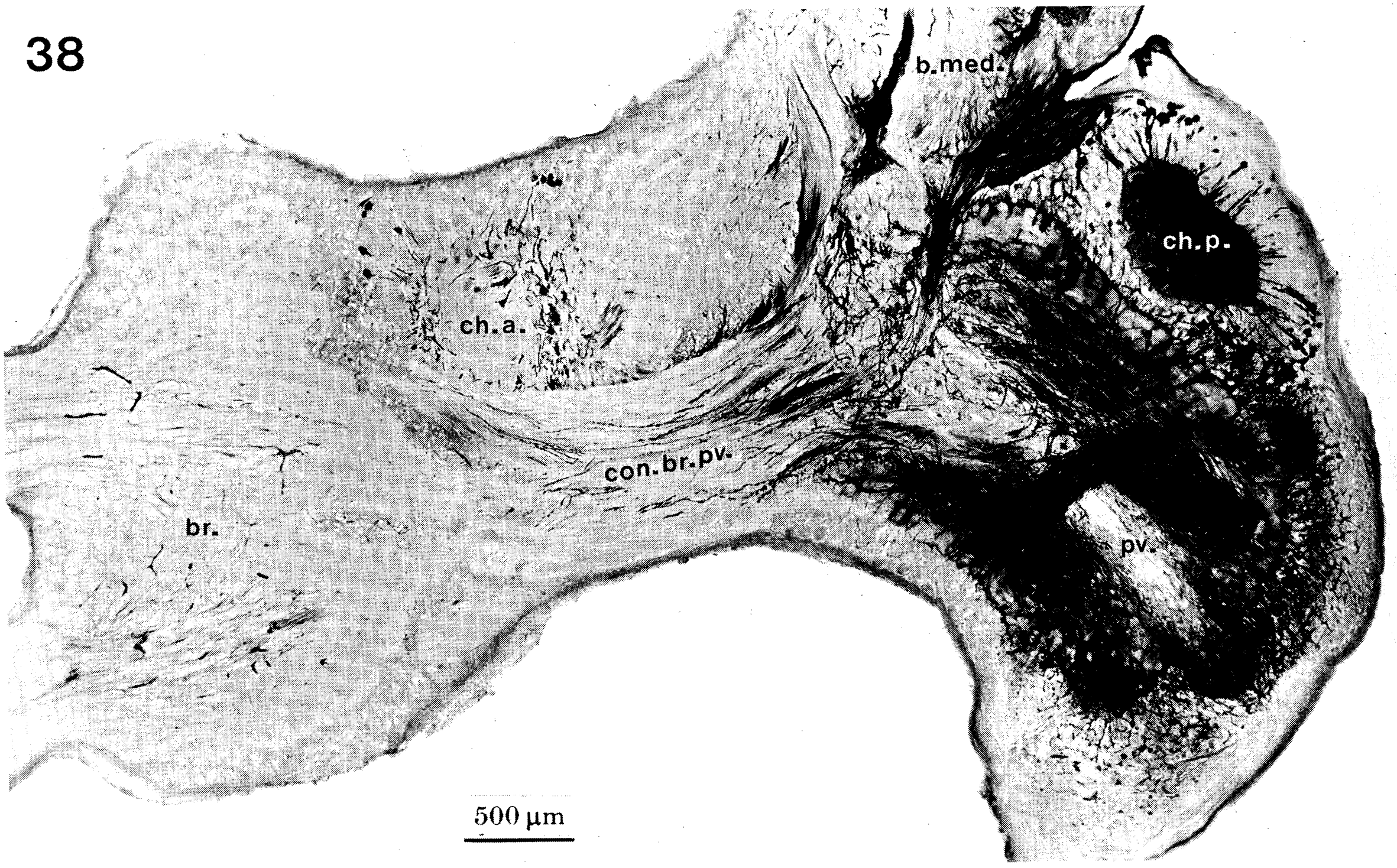

Figures 37 and 38. For description see opposite:

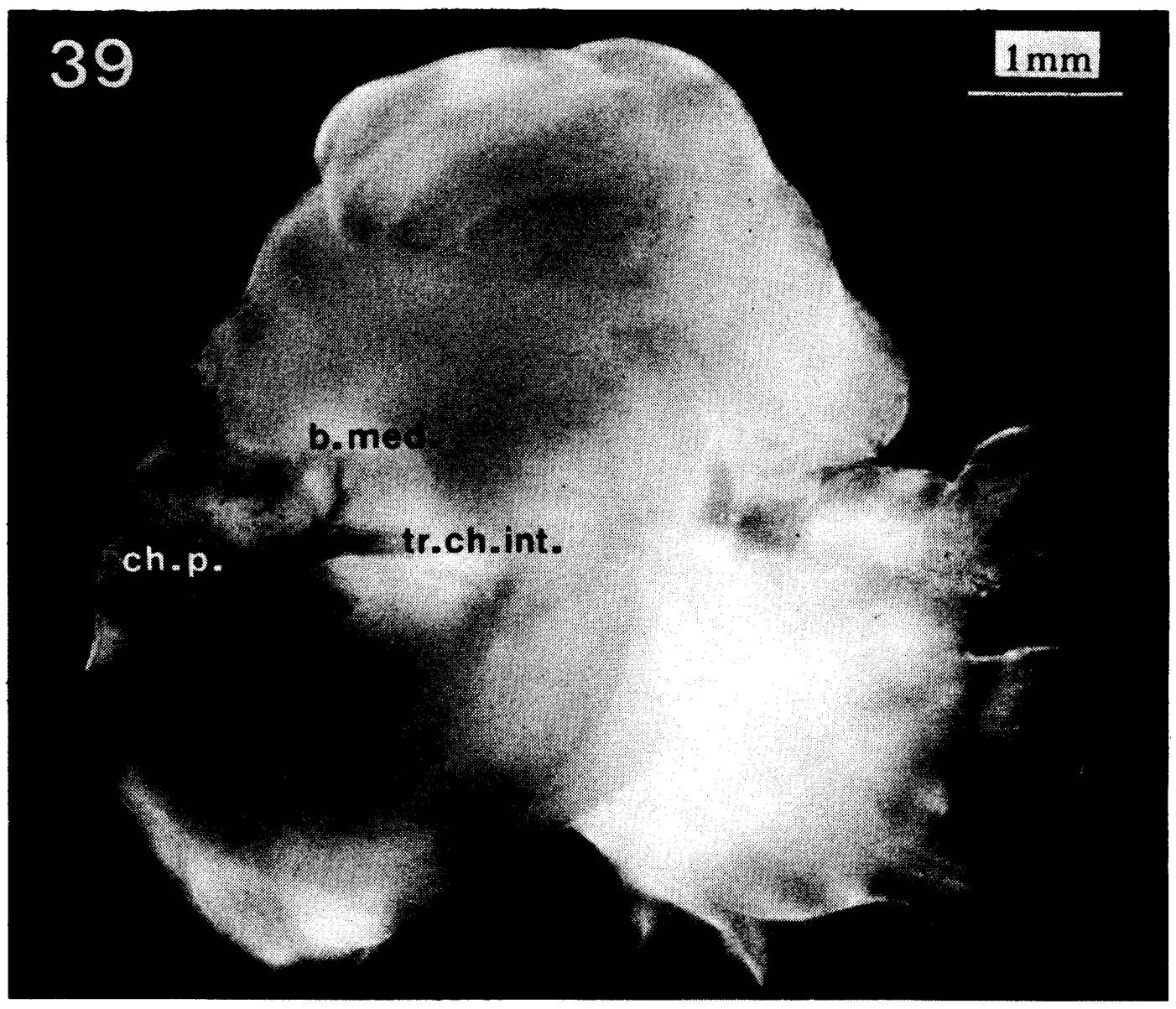

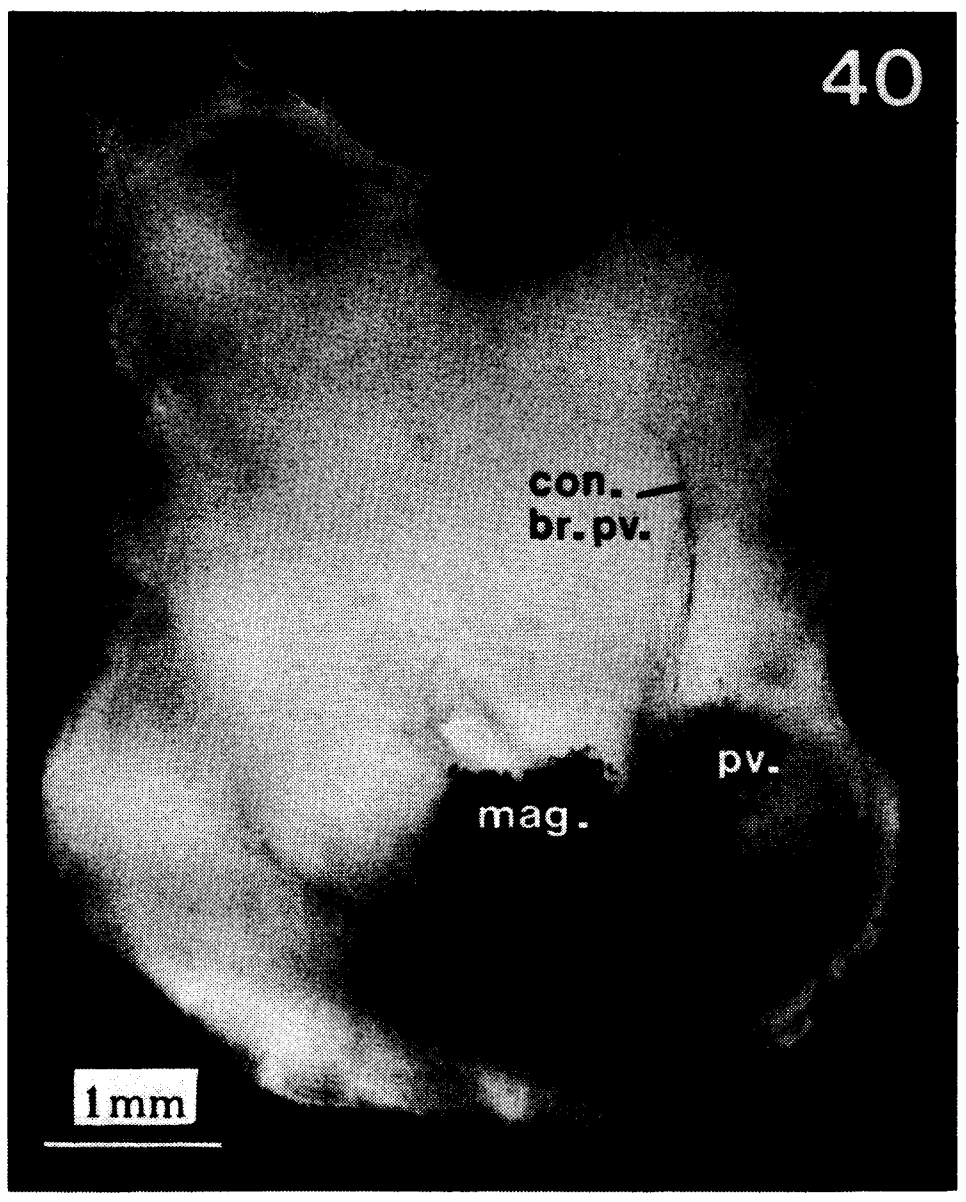

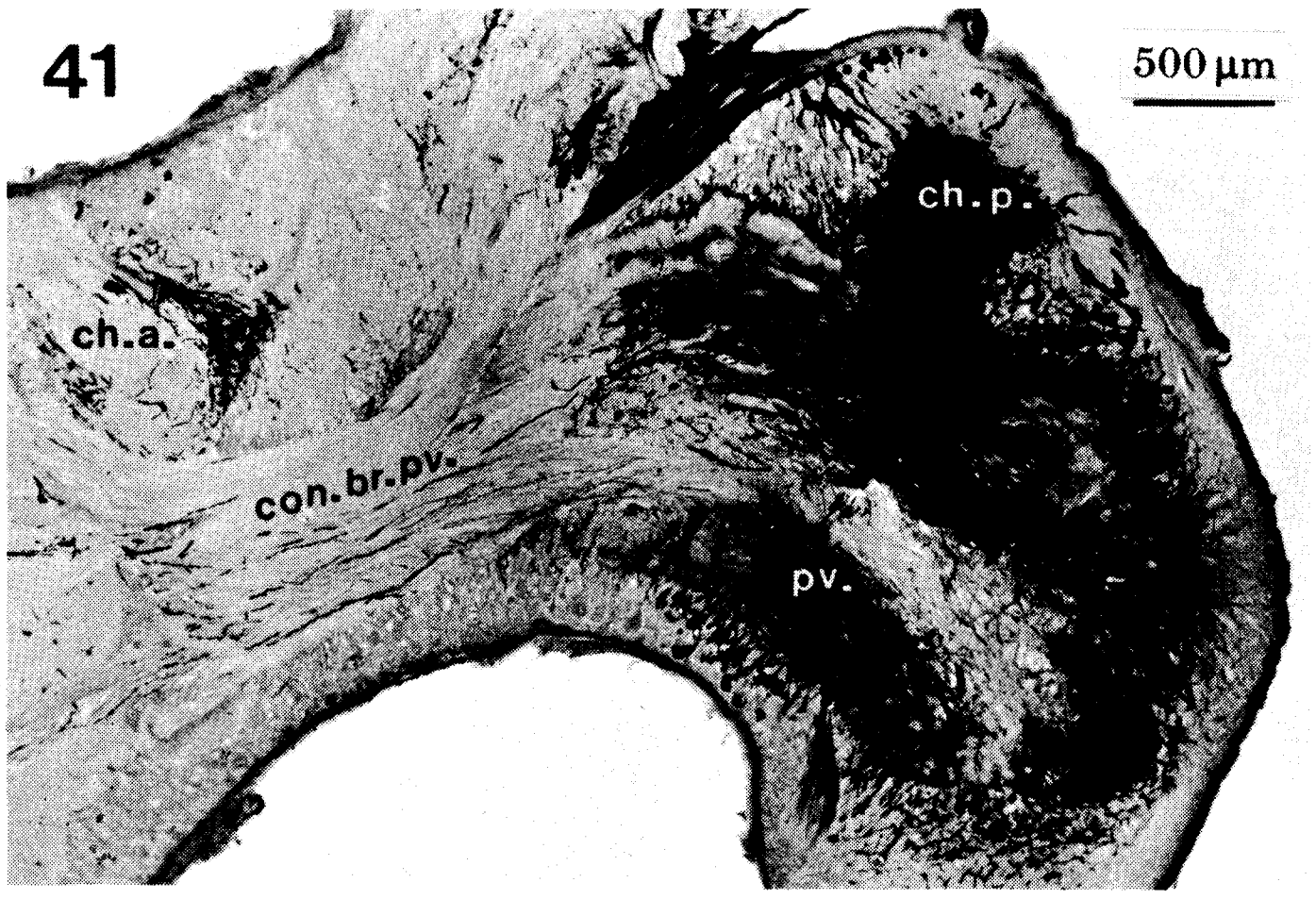

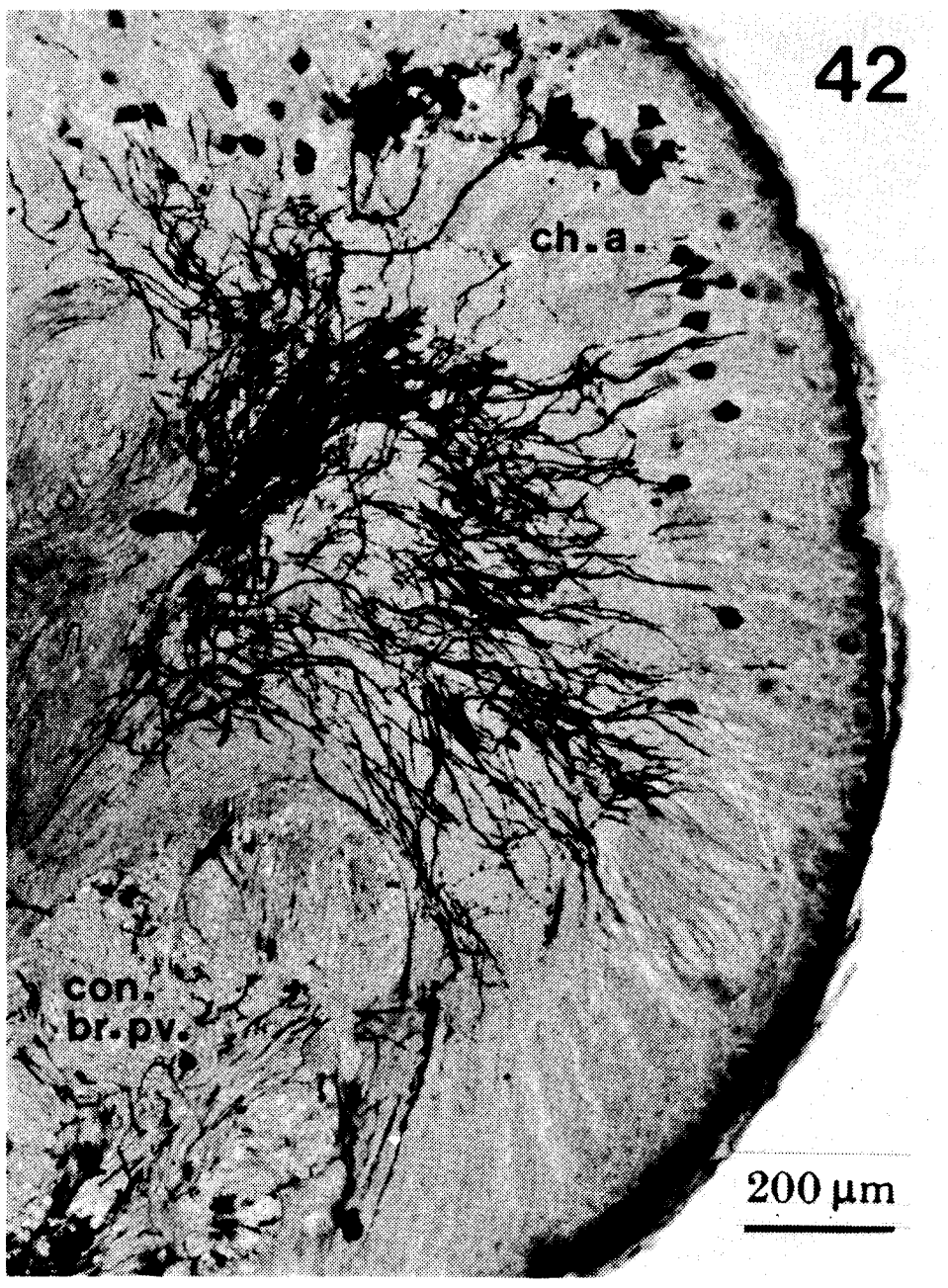



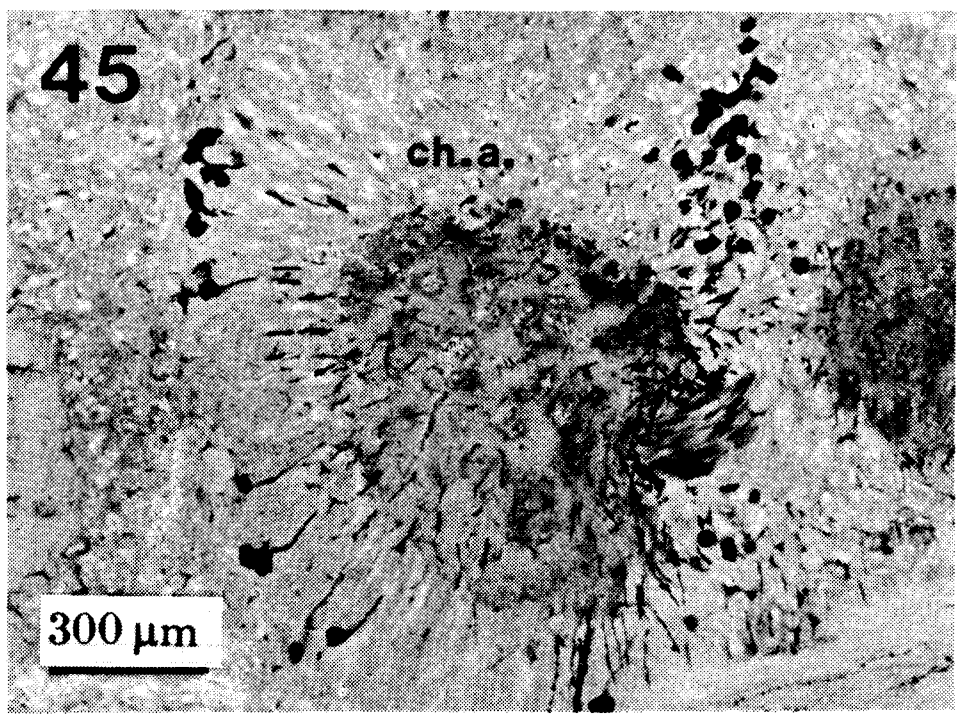

FIGURES 39–45. For description see p. 116.

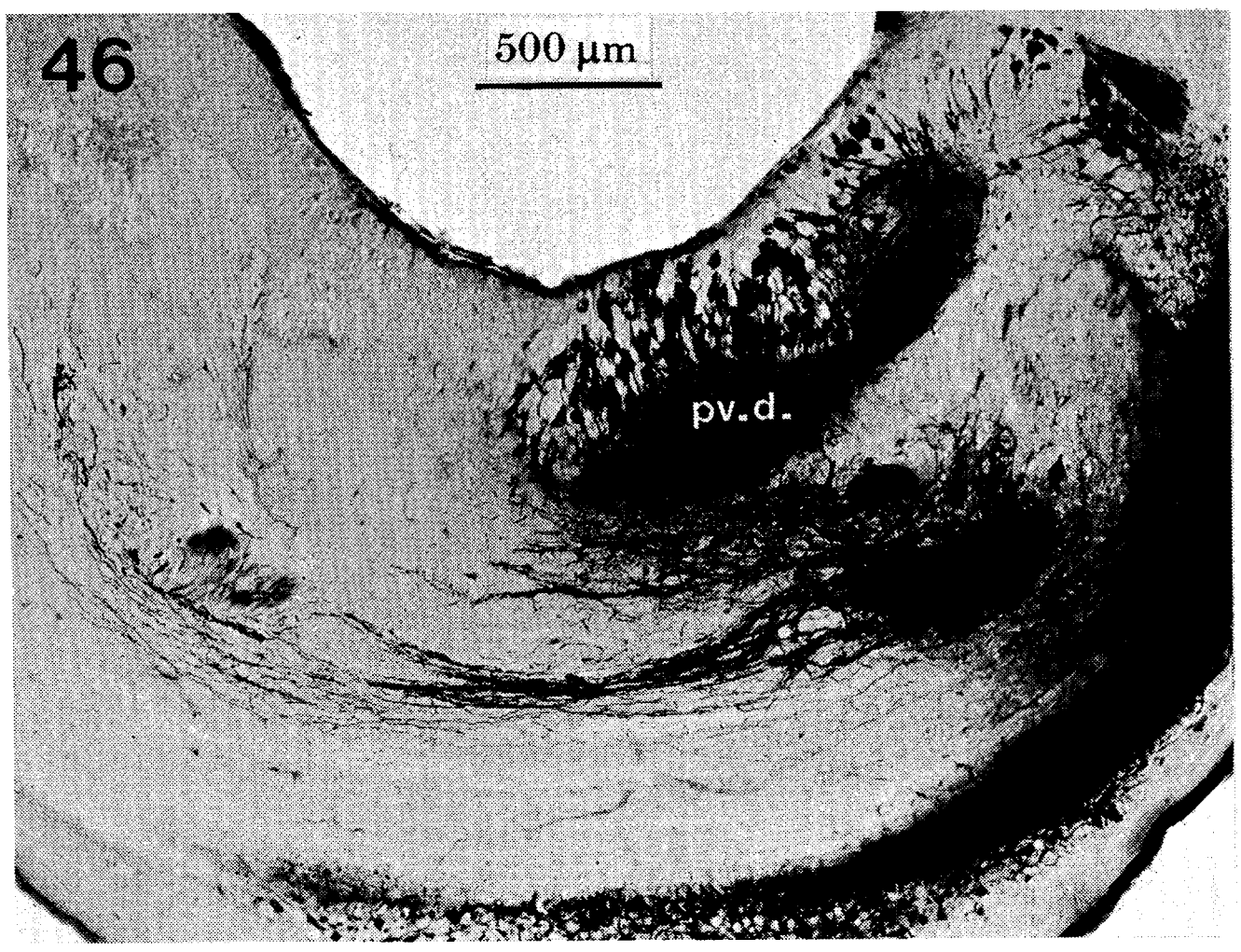

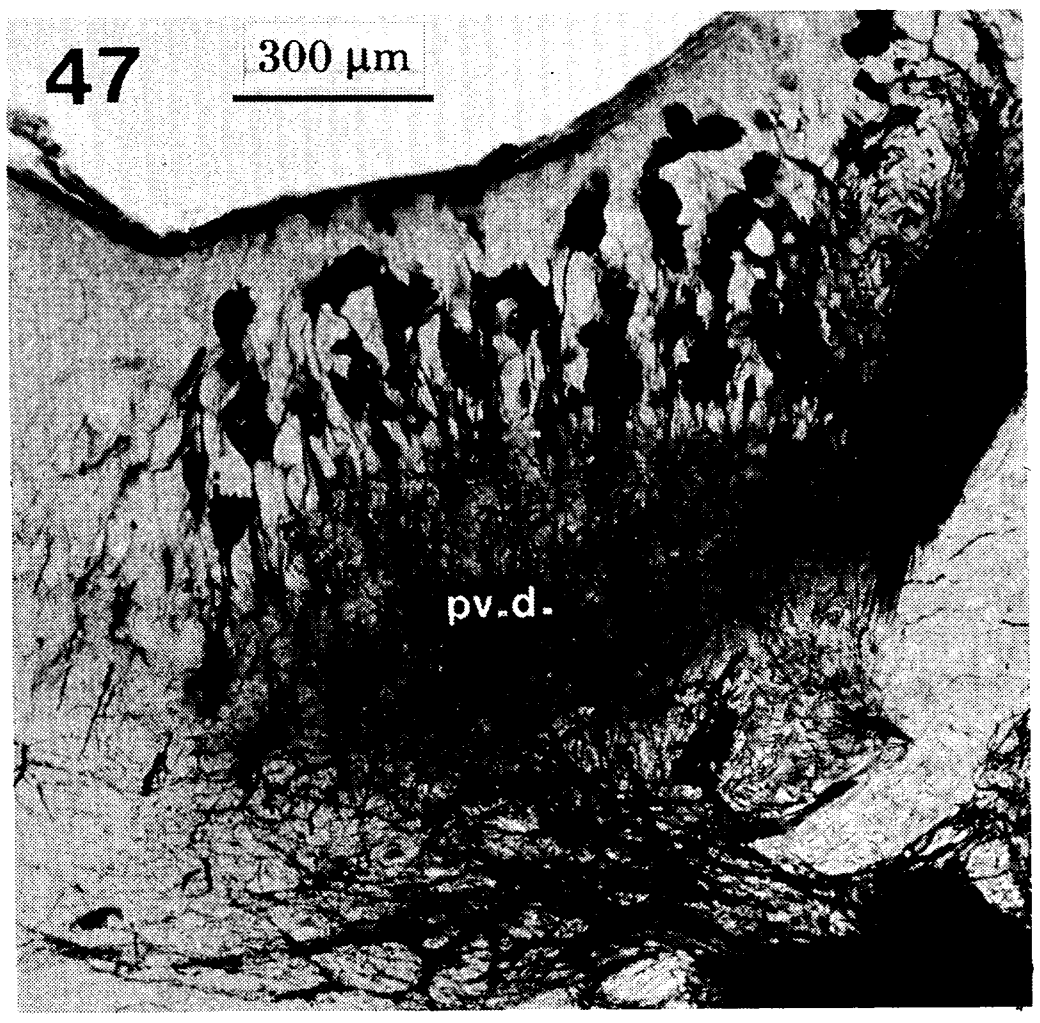



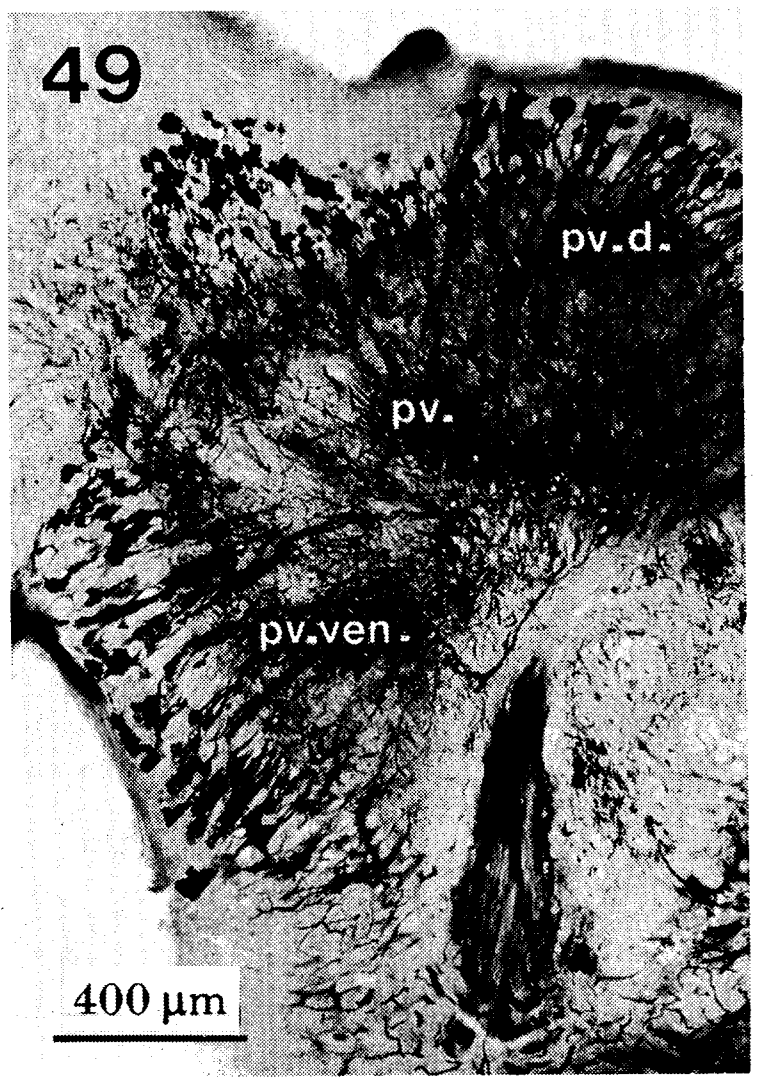

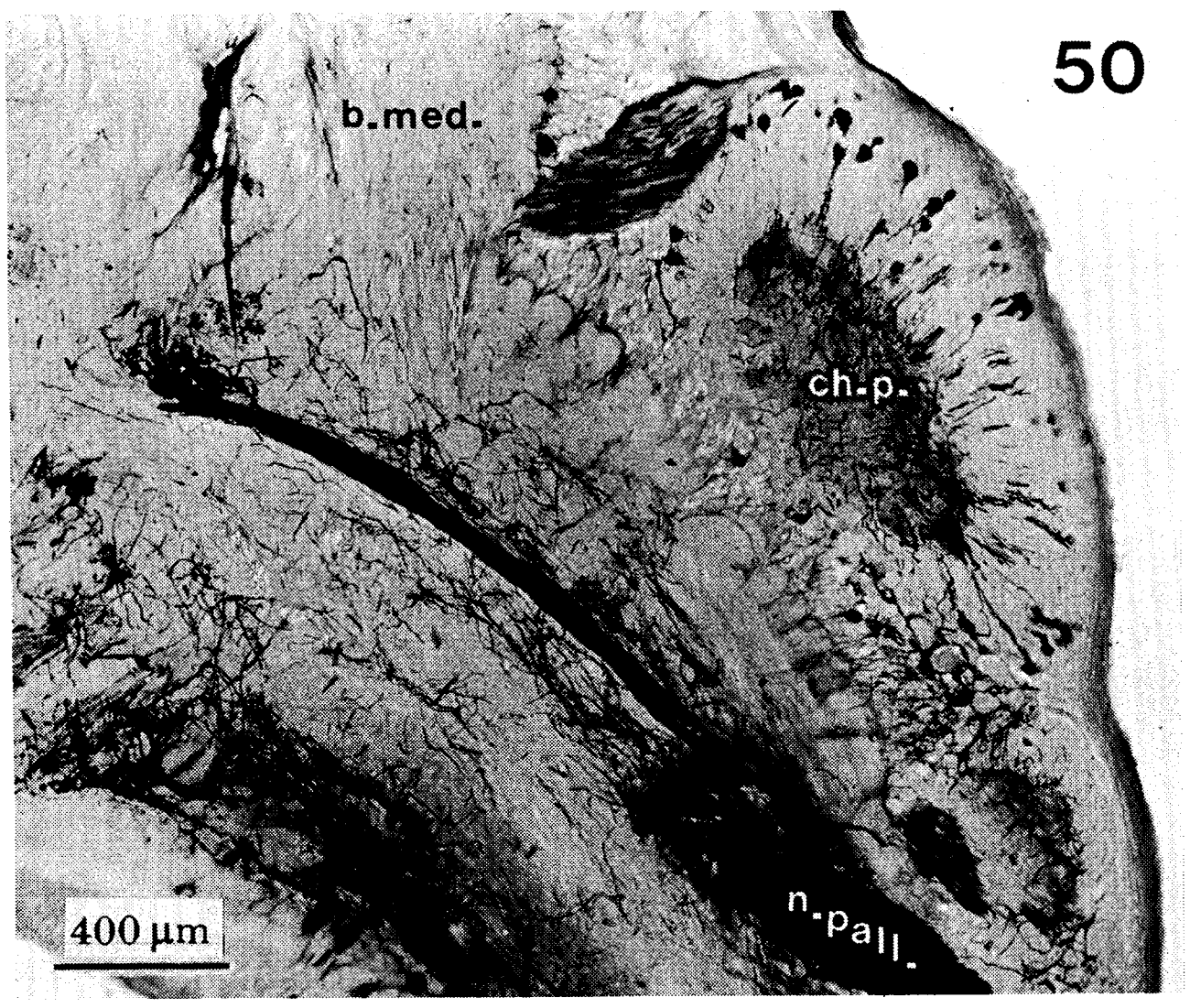



FIGURES 46–51. For description see p. 117.

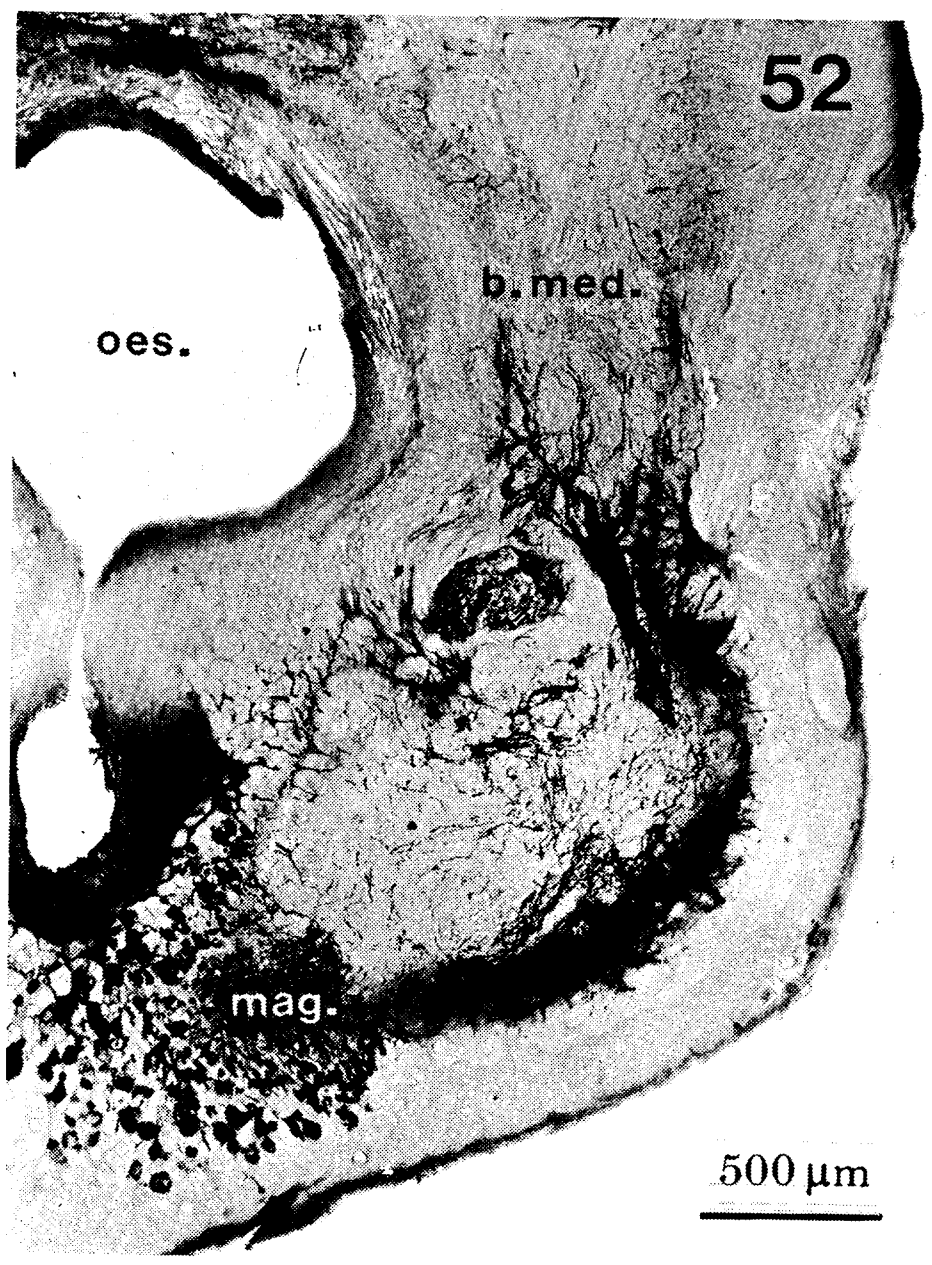

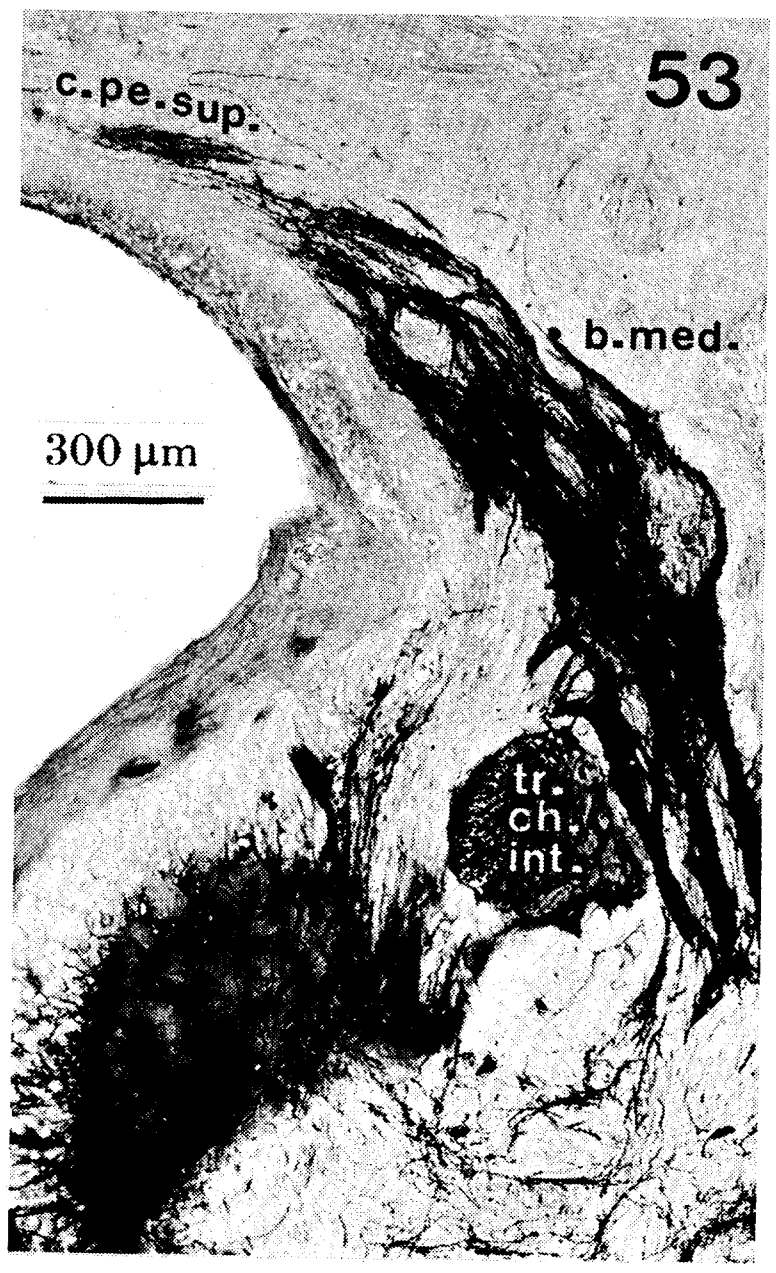

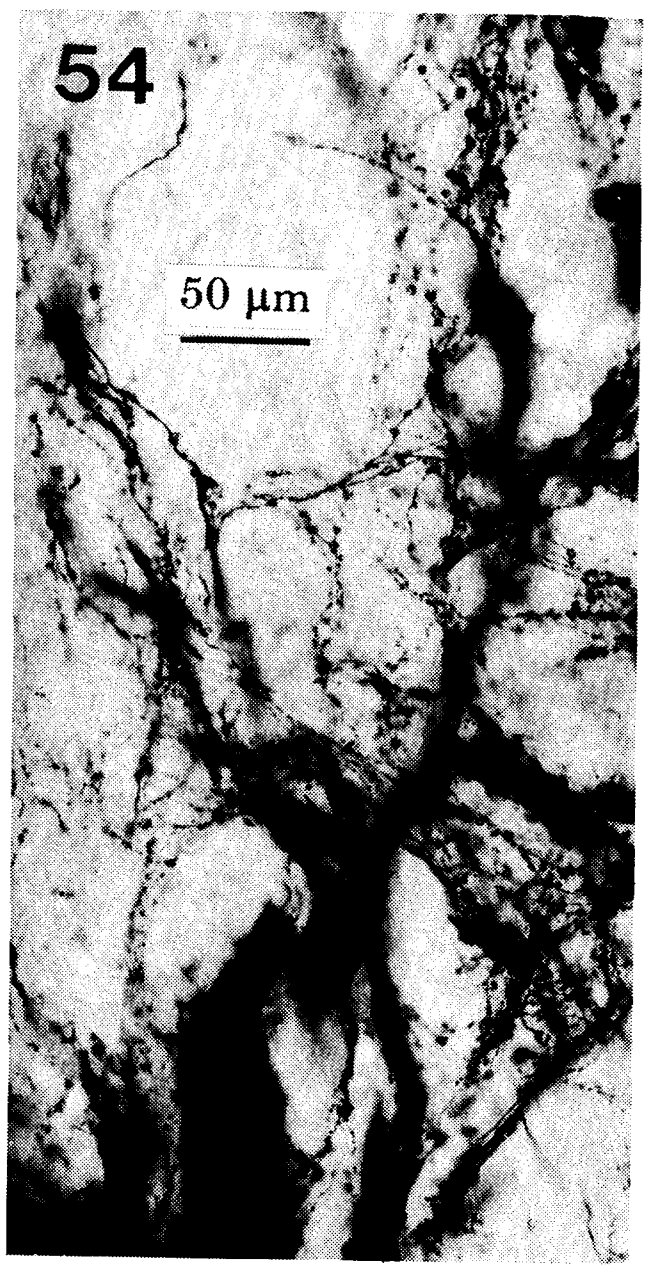

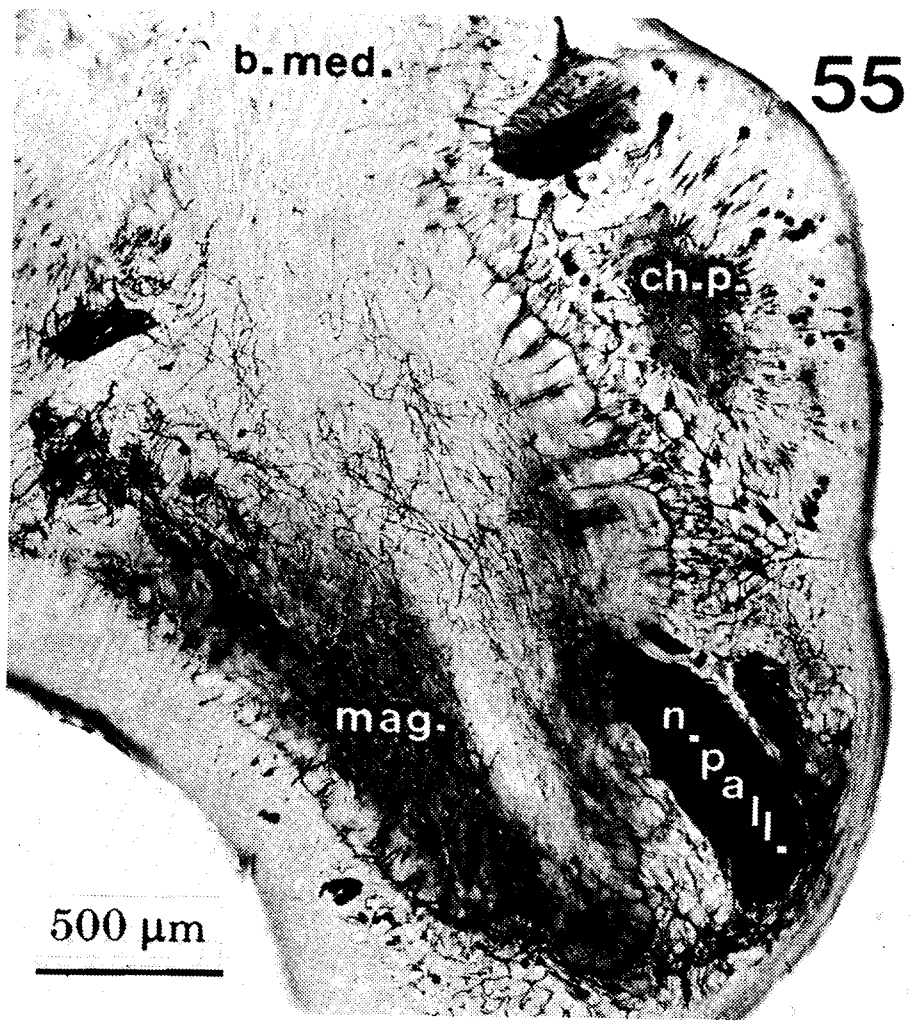

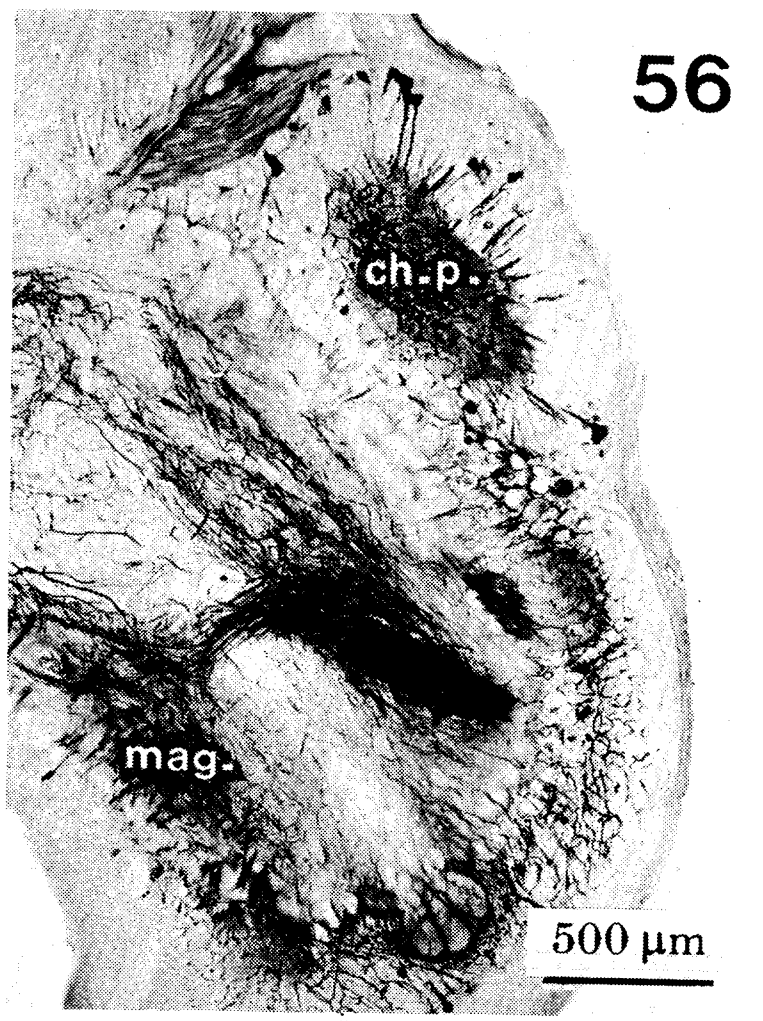

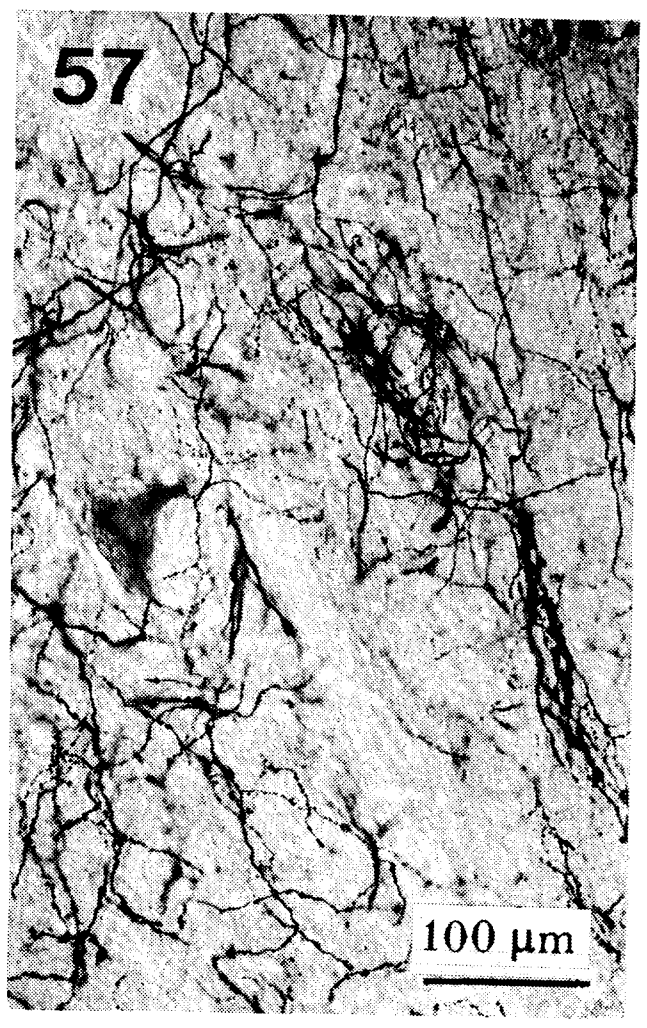

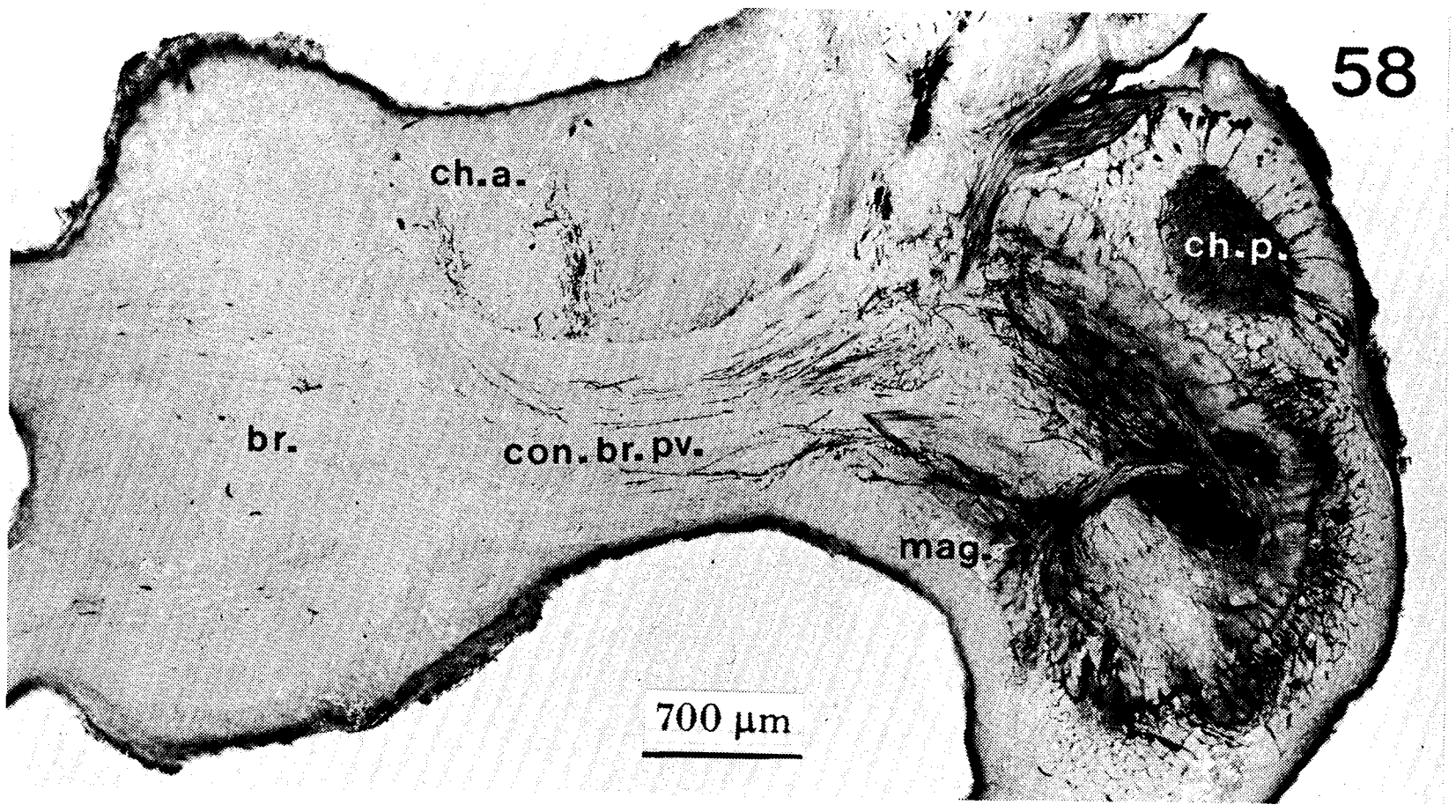

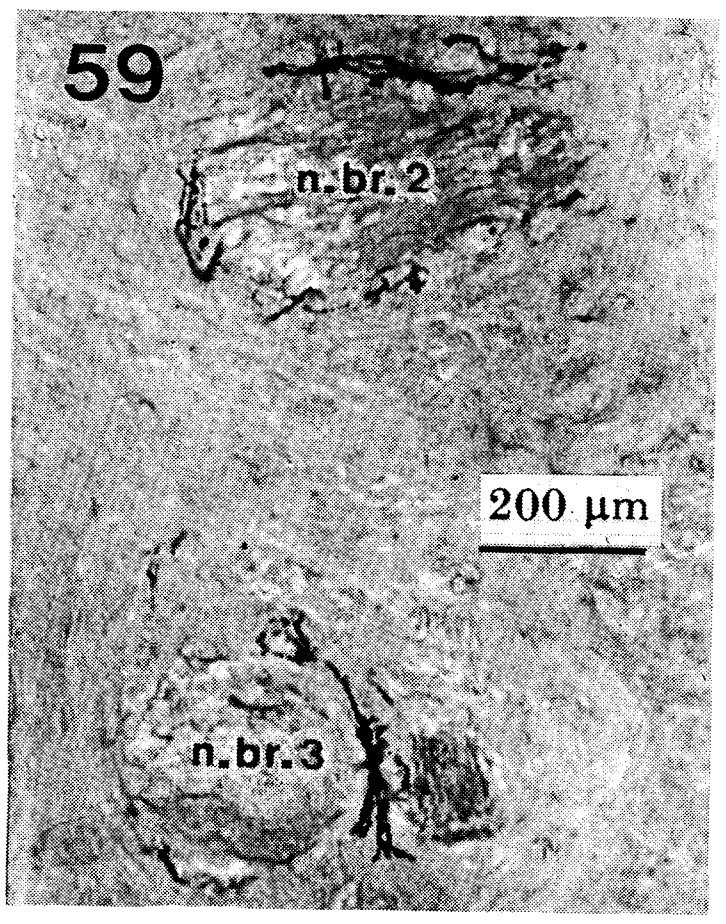

FIGURES 52–59. For description see opposite.

and here some enter the brachiopalliovisceral lobe connective and continue forwards to the brachial lobes.

(v) Fibres to the brachial lobe. Fibres filled in the brachiopalliovisceral lobe connective run forwards to the brachial lobe (figures 38, 41, 48 and 58). They arise in isolated bundles from the centre of the palliovisceral lobe and from the front of the magnocellular lobe. The fibres branch within the brachial lobe and are probably afferents. Some of the fibres proceed to the origin of the four ipsilateral brachial nerves. There, they wrap round the nerves (figure 59), but have not been seen to enter.

4. Discussion

The centripetal cobalt filling of the brachial and pallial nerves has given much useful information about several aspects of the functional organization of the *Octopus* brain. The afferent and efferent brain pathways are summarized diagrammatically in figures 60 and 61.

4.1. *The tactile learning system*

4.1.1. *The inferior frontal system*

The inferior frontal system is wholly concerned with learned tactile reactions (Wells & Young 1972; Young 1983). The centripetal cobalt fillings of the brachial nerves have produced valuable further evidence about its input and output pathways. The afferent fibres branch profusely in the lateral and median frontal lobes and many bundles cross the midline. There is thus a widespread distribution of the signals from one arm to all parts of the lobe (Young 1983). The filled fibres in the posterior buccal lobe are all large and are assumed to be efferents but we can not exclude the possibility that a few are afferents. No afferents pass direct to the subfrontal lobe, which receives its input from the median inferior frontal lobe (Young 1983).

Description of plate 9

Transverse (figures 46 and 47) and sagittal sections (figures 48–51) of the suboesophageal lobes of the *Octopus* brain after centripetal cobalt filling of the pallial nerve.

Figures 46 and 47. Somata in the dorsal palliovisceral lobe and fibres crossing through the palliovisceral commissure to the contralateral side.

Figure 48. Bundle of fibres in the palliovisceral lobe running medially downwards and forwards, and somata along the medial ventral surface of the lobe.

Figure 49. Somata in the dorsal and ventral palliovisceral lobe. A group of small somata can be seen dorsally in the anterior wall of the lobe.

Figures 50 and 51. Bundle of fibres running to the median basal lobe, with a few somata at the lower margin of the lobe. Many somata are seen in the posterior chromatophore lobe.

Description of plate 10

Transverse (figures 52–54 and 59) and sagittal sections (figures 55–58) of the suboesophageal lobes of the *Octopus* brain after centripetal cobalt filling of the pallial nerve.

Figure 52. Somata at the front of the ventral magnocellular lobe, and afferent fibres proceeding to the median basal lobe.

Figures 53 and 54. Afferent fibres in the median basal lobe, some of which cross in the suprapedal commissure.

Figures 55, 56 and 58. Fibres turning downwards towards the ventral magnocellular lobe, and few somata along the floor of the lobe. Many somata are seen in the posterior chromatophore lobe.

Figure 57. Afferent fibres in the magnocellular lobe.

Figures 58 and 59. Afferent fibres in the brachiopalliovisceral lobe connective running forwards to the brachial lobe; some proceed to the origin of the brachial nerves.

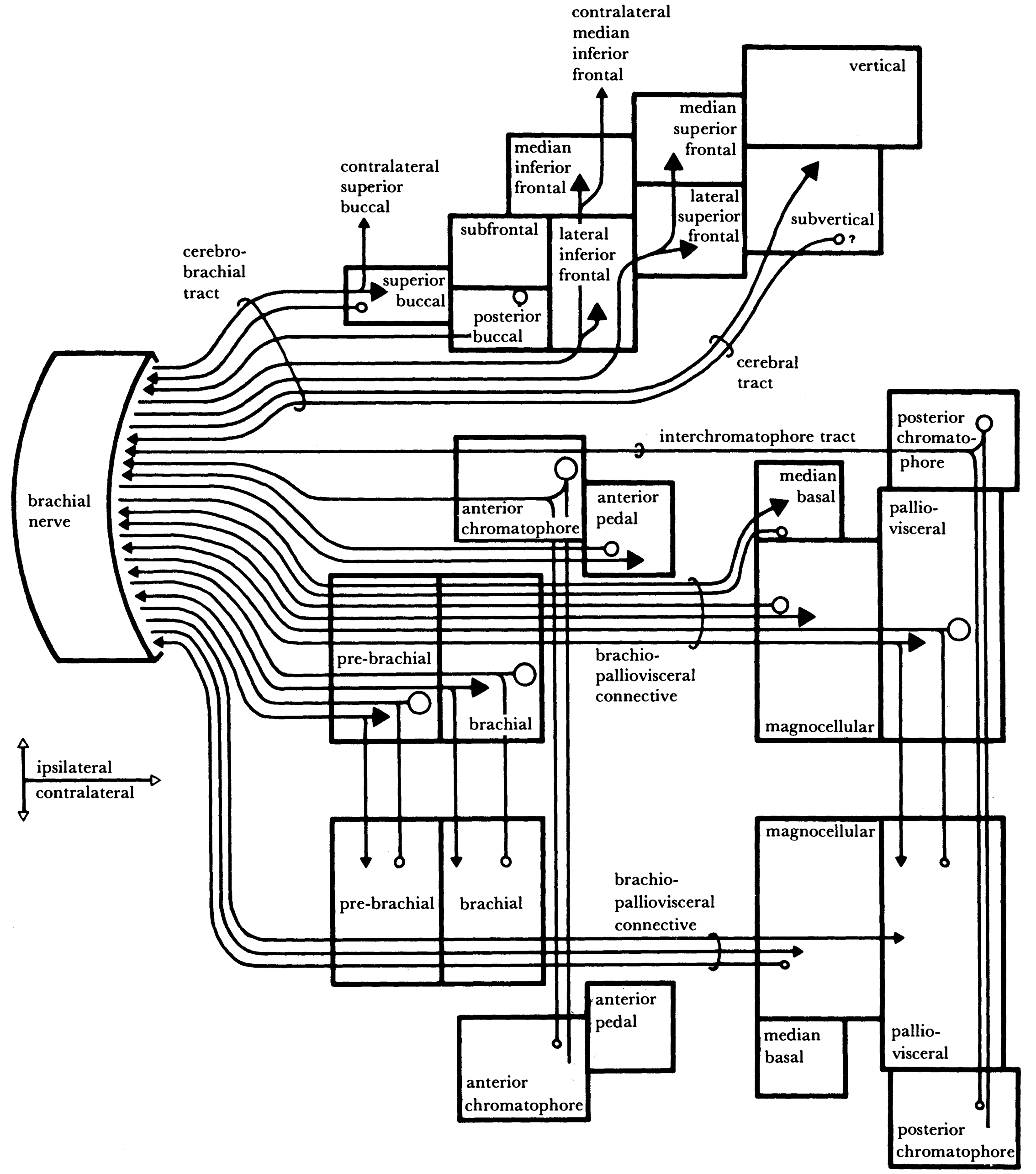

FIGURE 60. Schematic presentation of the afferent and efferent brain pathways of the third brachial nerve of *Octopus vulgaris*, as obtained by centripetal cobalt filling. The rectangles represent the brain lobes as indicated. The relevant contralateral lobes are shown only for the suboesophageal mass of the brain. Open circles indicate the origin (that is, the somata) of the pathways and arrowheads their termination. The sizes of the open circles or arrowheads provide an approximate indication of the number of cells or fibres filled. Large open circles indicate many filled somata, small open circles few. Large arrowheads indicate the termination of many filled afferents, small arrowheads of few. When branched lines are shown they indicate continuation of the pathway, not necessarily of individual fibres. In the subvertical lobe some of the fibres are large and presumed to be of efferents, but their somata were not found.

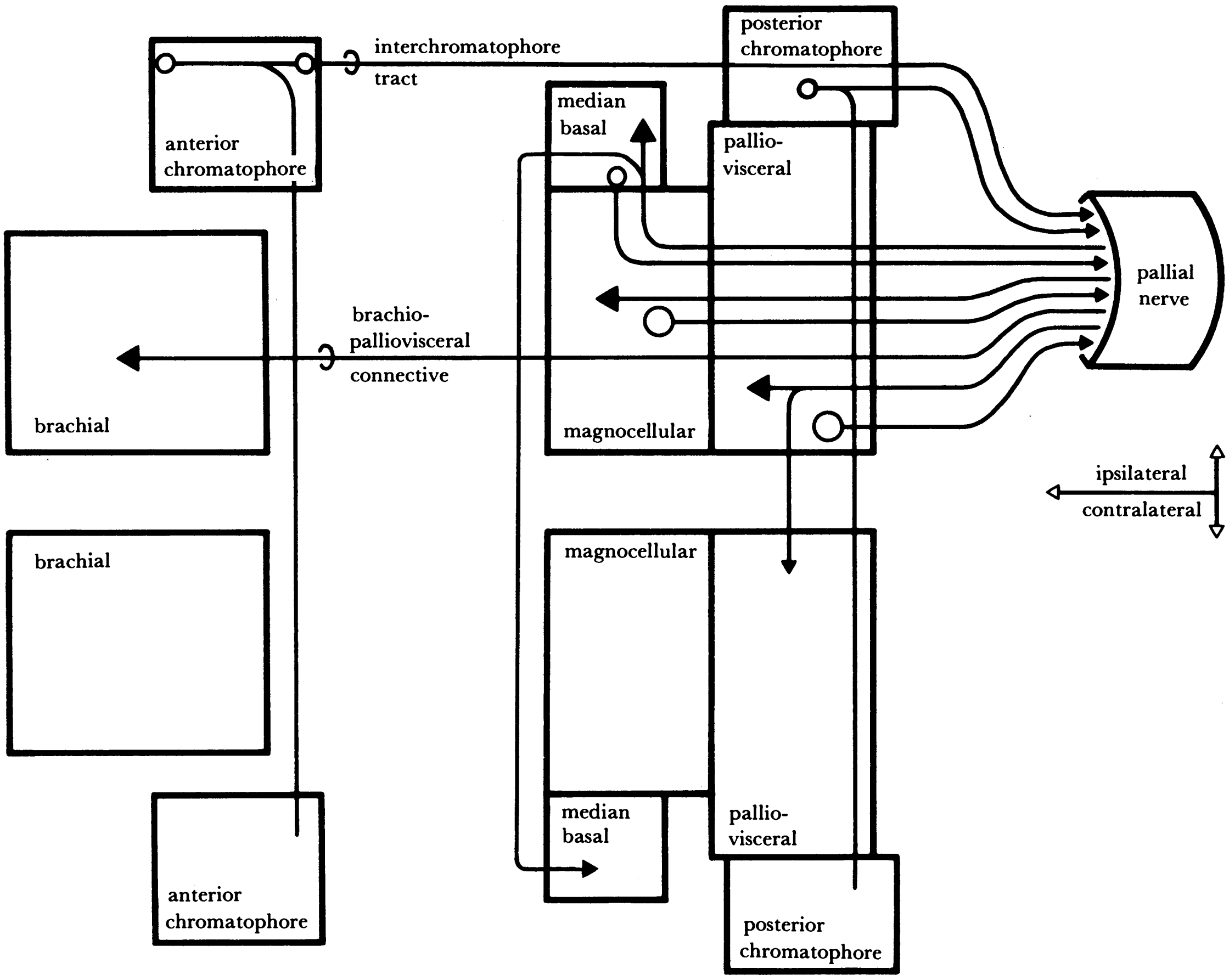

FIGURE 61. Schematic presentation of the afferent and efferent brain pathways of the pallial nerve of *Octopus vulgaris*, as obtained by centripetal cobalt filling. Conventions as for figure 60.

Large somata were filled in the posterior buccal lobe. These are of special interest as forming the final common pathways for the learned tactile reactions. They occur mostly close to the base of the subfrontal lobe and are presumably controlled by its output fibres. No somata were filled in the subfrontal lobe itself.

Degenerating fibres have been seen after section of the cerebrobrachial tracts in the brachial and prebrachial lobes and in the brachial nerves (Young 1971). The present fillings now provide evidence of the cells from which they arise. The absence of filled somata in the lateral and median inferior frontal lobes confirms that any descending fibres from these lobes end in the anterior suboesophageal mass of the brain and do not proceed to the arms (Young 1971).

4.1.2. *The superior frontal–vertical lobe system*

The superior frontal and vertical lobes are also known to participate in tactile learning (Sanders 1974, for a review; Young 1983). It is therefore very interesting that the fillings from the brachial nerve show the afferent and perhaps also the efferent fibres that are involved. Afferent fibres from the brachial nerve were filled in the lateral and median superior frontal lobes. This is the first demonstration that the interfrontal tracts contain fibres originating in the arms. These presumably provide the information about objects touched, which is then passed on to the vertical lobes. Many of the fibres that were filled in the cerebral tracts were afferents to the subvertical lobes. Perhaps these are nocifensor (pain) fibres (Young 1983). They reach to the top of the subvertical lobe but none enter the vertical lobe itself.

The few large filled fibres in the cerebral tract are probably efferent axons to the arms. Their somata have not been seen but may be among the large cells of the lateral subvertical lobe (Young 1971). Large descending fibres have already been seen degenerating in the cerebrobrachial tracts after lesions to the subvertical lobes (J. Z. Young, unpublished observations). These are presumably the fibres that carry the output signals from the vertical lobe system in learned tactile discriminations. It would be interesting to investigate further the possible responses of the arms after electrical stimulation of these fibres and those that arise in the posterior buccal lobe.

4.2. *The chromatophore lobes*

Both the anterior and posterior chromatophore lobes contribute motoneurons to both the arms and the mantle. This rather surprising fact was not shown by previous studies (Froesch 1973). It would be interesting to discover if there are cells common to the arms and the mantle in both lobes serving to produce a particular colour pattern. The functional significance of the arrangement of the somata only anteriorly and posteriorly in the anterior chromatophore lobe after cobalt filling of the pallial nerve remains unclear.

No afferent fibres were seen in the chromatophore lobes after filling the pallial nerve, and few (if any) in the anterior chromatophore lobe after filling of the brachial nerve. Therefore, the greater part of the control of colour changes presumably comes through the eyes and the lateral basal lobe.

4.3. *Control of the arms*

The significance for behaviour of the many cells and afferent fibres of the prebrachial, brachial and anterior pedal lobes is not clear. Electrical stimulation of the anterior suboesophageal mass of the *Sepia* brain always produced movements of all the arms on both the right and the left side of the animal (Boycott 1961). This agrees with the wide distributions of the filled somata within the brachial lobe in *Octopus*. Boycott (1961) found evidence that the tracts of fibres originating in the anterior pedal lobe produce movements of individual arms. Stimulating the anterior pedal lobe itself sometimes produced extension of the tentacles or raising of the first two arms. It is possible that individual arm movements are organized here. The function of the afferent fibres from the pallial nerve that reach to the brachial lobe remains to be discovered.

4.4. *The magnocellular lobe*

Many somata and afferent fibres were filled in the magnocellular lobe from both the brachial and the pallial nerves. The presence of these afferent fibres had already been shown by degeneration (Young 1971) but this is the first evidence that efferent fibres to these nerves arise here. The filled somata are especially numerous at the front of the ventral part of the lobe. Some of these send large fibres to the pallial nerve. They have very long dendrites receiving stimulation from a large part of the magnocellular and probably also the palliovisceral lobes. They are presumably axons producing avoidance reactions, but it is not clear where they end. The front of the ventral part of the magnocellular lobe is probably a region that initiates strong escape reactions. In decapods, it contains the first-order giant cell (Young 1976). The magnocellular lobe receives afferent fibres from the optic lobe, statocyst, surface of the head, and probably other regions as well (Young 1971; Budelmann & Young 1984). Electric stimulation of this region in *Sepia* produced violent expiration (Boycott 1961). It is not clear how the avoidance reactions are produced in *Octopus*. By analogy with the giant fibres of decapods, it would be expected that fibres of the magnocellular lobe would end in the palliovisceral lobe (Young 1976). But the large fibres described in §3.2.2.2. were filled from the pallial nerve and presumably pass to the stellate ganglion.

4.5. *The median basal lobe*

Many afferent fibres reach to the base of the median basal lobe from both the brachial and the pallial nerves. They make an elaborate plexus here. A few somata were filled at the lower edge of this lobe, but they may perhaps more properly be considered as part of the magnocellular lobe. This region at the base of the median basal lobe also receives afferent fibres from the posterior root of the posterior superior ophthalmic and superior antorbital nerves (Young 1971; Budelmann & Young 1984). Possibly these fibres represent those from the pre- and postocular tentacles in *Nautilus* (Young 1965). This region may be a centre controlling avoidance reactions, perhaps through connections with the nearby magnocellular lobe. In *Sepia*, stimulation of the median basal lobe had various effects, including placing the arms together in the midline, raising of the first or second pair of arms, or both, to the attention position, respiratory and swimming movements, and giant fibre responses (Boycott 1961; Chichery 1983).

4.6. *The palliovisceral lobe*

The afferent fibres of the pallial nerve presumably largely arise from receptors in the skin of the mantle. Some of them may be the central ends of the cells of the stellate ganglion that were filled with cobalt and horseradish peroxidase applied to the peripheral end of the pallial nerve (Monsell 1980; Monsell & Cottee 1980). The somata that we have seen filled in the wall of the palliovisceral lobe presumably largely provide presynaptic fibres to the stellate ganglion, for the control of the mantle. Some of these may be concerned with respiration, others with locomotion, but it has not been possible to separate these. Other cells of the palliovisceral lobe provide the axons that control the muscles of the capsule around the digestive gland (Young 1971).

The function of the cells in the palliovisceral lobe whose axons pass towards the brachial nerves remains unknown. Some of the more posterior of them may belong to the vasomotor lobes, which are not shown in figure 61. It is interesting that both cells and fibres of the palliovisceral lobe may be connected with the brachial nerve through the brachiopalliovisceral lobe connective of either the same or the opposite side.

4.7. *Absence of optic connections*

We have seen no evidence of fibres proceeding direct to the optic lobes from either the brachial or pallial nerves. No such fibres appeared in the brachio-optic tract or dorsal magnocellular lobe, which provide possible pathways (Young 1971). Another pathway that has been suggested is from the brachial nerves through the inferior frontal system (Young 1971), but we saw no filled fibres with this direction. Negative evidence of this sort cannot be wholly convincing, the fibres may be present but not filled (see Budelmann & Young 1984).

This work was supported by grants of the Deutsche Forschungsgemeinschaft (B.U.B.: Bu 404/3-2 and SFB 4) and the Wolfson Foundation (J.Z.Y.). The authors would like to thank the Director and staff of the Zoological Station in Naples, Italy, for their hospitality and continuous help, M. Staudigl for excellent technical assistance and H. Hallmer, R. Nowack and P. R. Stephens for photography. We are also grateful to the Wellcome Institute for the History of Medicine for accommodation.

REFERENCES

Boycott, B. B. 1961 The functional organization of the brain of the cuttlefish *Sepia officinalis*. *Proc. R. Soc. Lond.* B **153**, 503–534.

Budelmann, B. U. & Young, J. Z. 1984 The statocyst–oculomotor system of *Octopus vulgaris*: extraocular eye muscles, eye muscle nerves, statocyst nerves, and the oculomotor centre in the central nervous system. *Phil. Trans. R. Soc. Lond.* B **306**, 159–189.

Chichery, R. 1983 Motor and behavioural responses obtained by electrical stimulation of peduncle and basal lobes: the control of visual-static centres on oculomotor reactions and locomotion in the cuttlefish, *Sepia officinalis*. *Fortschr. Zool.* **28**, 231–240.

Froesch, D. 1973 Projections of chromatophore nerves on the body surface of *Octopus vulgaris*. *Mar. Biol.* **19**, 153–155.

Monsell, E. M. 1980 Cobalt and horseradish peroxidase tracer studies in the stellate ganglion of *Octopus*. *Brain Res.* **184**, 1–9.

Monsell, E. M. & Cottee, L. J. 1980 Retrograde intraaxonal transport of horseradish peroxidase by neurones in *Octopus*. *Brain Res.* **181**, 251–258.

Sanders, G. D. 1974 The cephalopods. In *Invertebrate learning*, vol. 3 (ed. W. C. Corning, J. A. Dyall & A.O.D. Willows), pp. 1–101. London and New York: Plenum Press.

Tyrer, N. M. & Bell, E. M. 1974 The intensification of cobalt-filled neurone profiles using a modification of Timm's sulphide–silver method. *Brain Res.* **73**, 151–155.

Wells, M. J. & Young, J. Z. 1972 The median inferior frontal lobe and touch learning in *Octopus*. *J. exp. Biol.* **56**, 381–402.

Wells, M. J. & Young, J. Z. 1975 The subfrontal lobe and touch learning in the octopus. *Brain Res.* **92**, 103–121.

Young, J. Z. 1965 The central nervous system of *Nautilus*. *Phil. Trans. R. Soc. Lond.* B **249**, 1–25.

Young, J. Z. 1971 *The anatomy of the nervous system of Octopus vulgaris*. Oxford: Clarendon Press.

Young, J. Z. 1976 The nervous system of *Loligo*. II. Suboesophageal centres. *Phil. Trans. R. Soc. Lond.* B **274**, 101–167.

Young, J. Z. 1983 The distributed tactile memory system of *Octopus*. *Proc. R. Soc. Lond.* B **218**, 135–176.

ABBREVIATIONS USED ON THE FIGURES

b.a.	anterior basal lobe	mag.d.	dorsal magnocellular lobe
b.med.	median basal lobe	mag.ven.	ventral magnocellular lobe
br.	brachial lobe	n.br.1	first brachial nerve
br.pr.	prebrachial lobe	n.br.2	second brachial nerve
buc.p.	posterior buccal lobe	n.br.3	third brachial nerve
buc.sup.	superior buccal lobe	n.br.4	fourth brachial nerve
c.opt.ven.	ventral optic commissure	n.pall.	pallial nerve
c.ch.a.	anterior chromatophore commissure	oes.	oesophagus
		pe.a.	anterior pedal lobe
c.pe.med.	middle pedal commissure	pv.	palliovisceral lobe
c.pe.sup.	suprapedal commissure	pv.d.	dorsal palliovisceral lobe
ch.a.	anterior chromatophore lobe	pv.ven.	ventral palliovisceral lobe
ch.p.	posterior chromatophore lobe	subfr.	subfrontal lobe
con.br.pv.	brachiopalliovisceral lobe connective	subv.	subvertical lobe
		tr.br.b.med.	brachial to median basal lobe tract
fr.inf.	inferior frontal lobe		
fr.inf.l.	lateral inferior frontal lobe	tr.cer.br.	cerebrobrachial lobe tract
fr.inf.med.	median inferior frontal lobe	tr.ch.int.	interchromatophore lobe tract
fr.sup.	superior frontal lobe	v.l.	vasomotor lobe
mag.	magnocellular lobe		

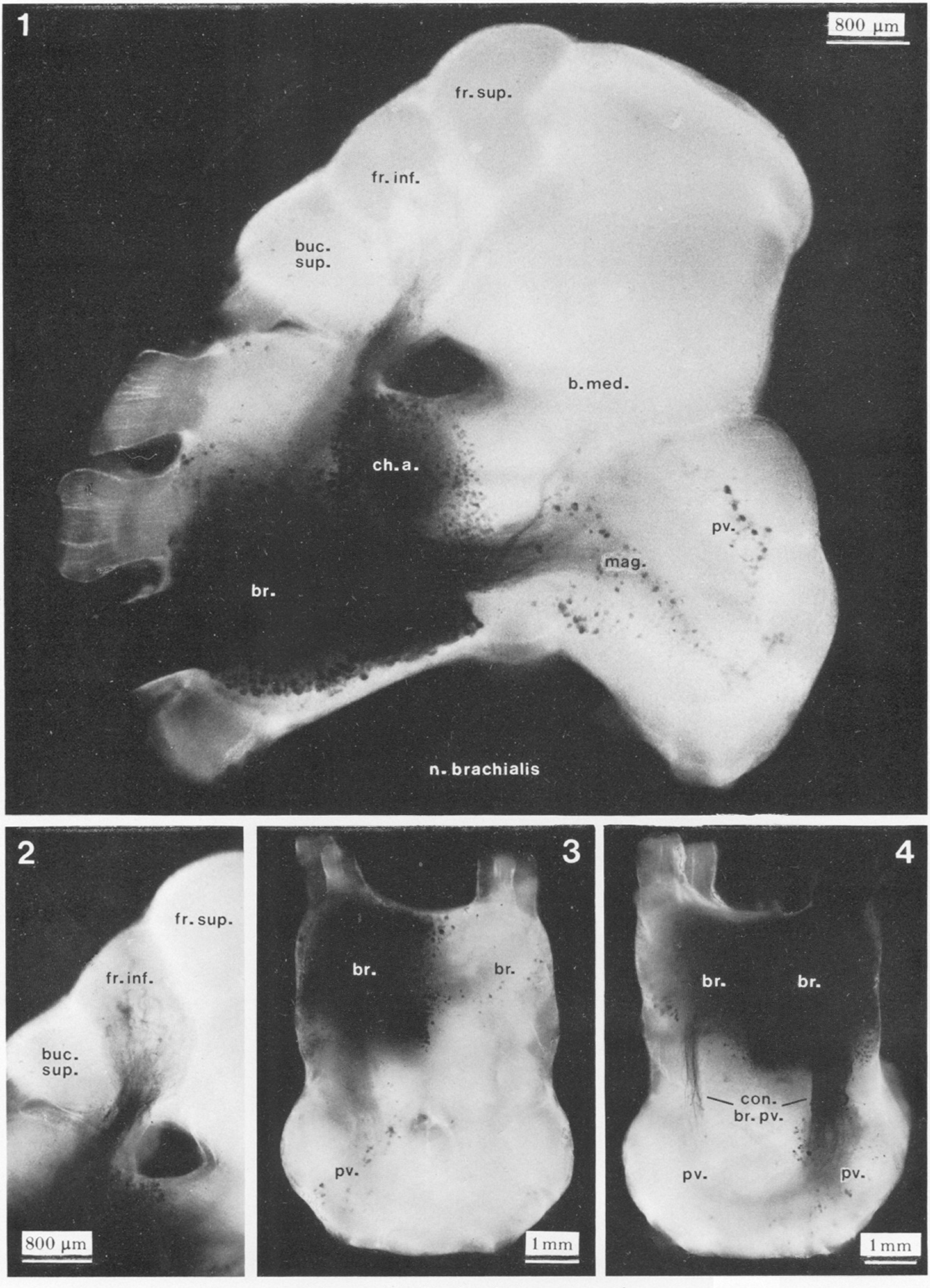

Figures 1–4. For description see opposite.

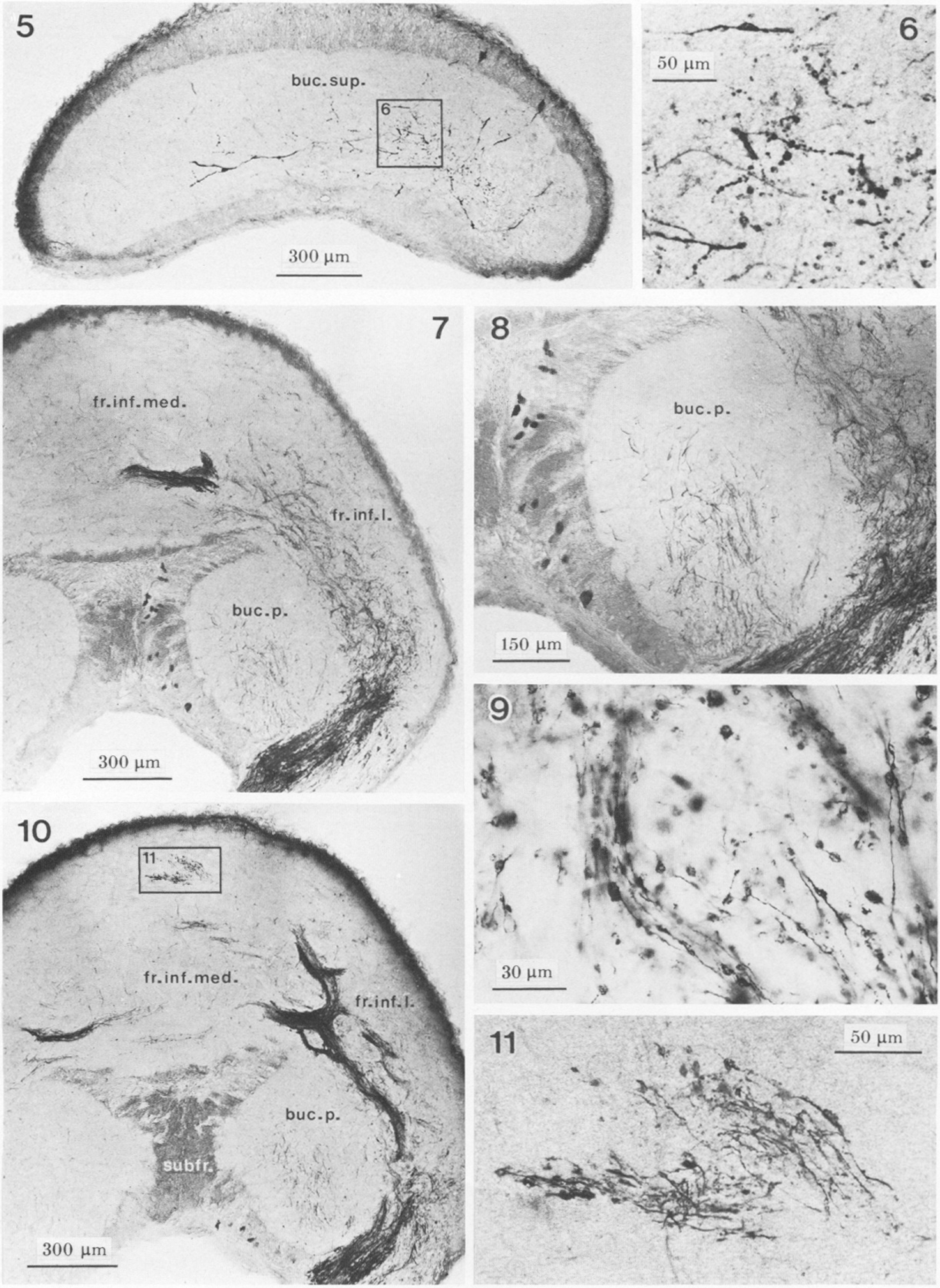

FIGURE 5–11. For description see p. 112.

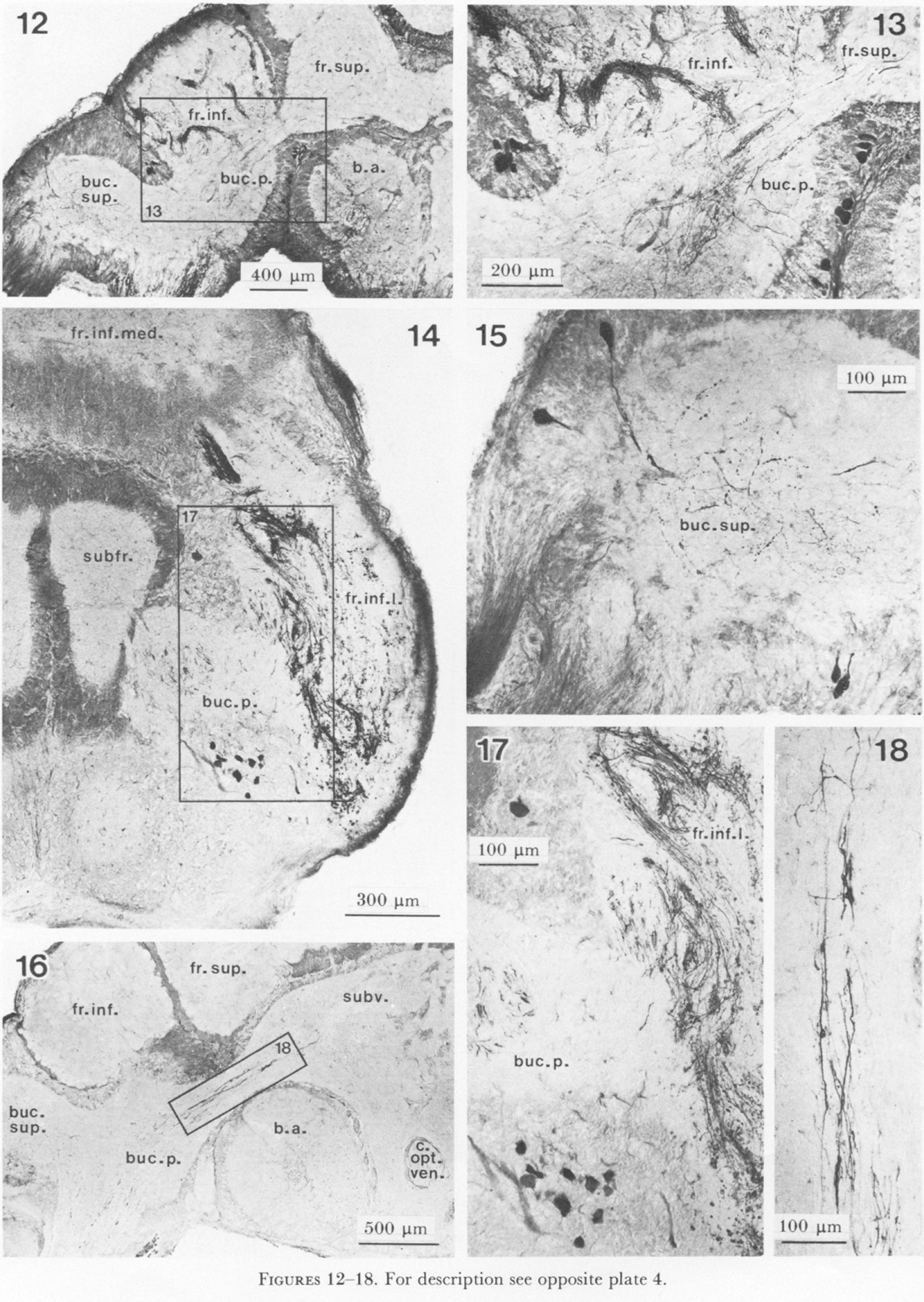

FIGURES 12–18. For description see opposite plate 4.

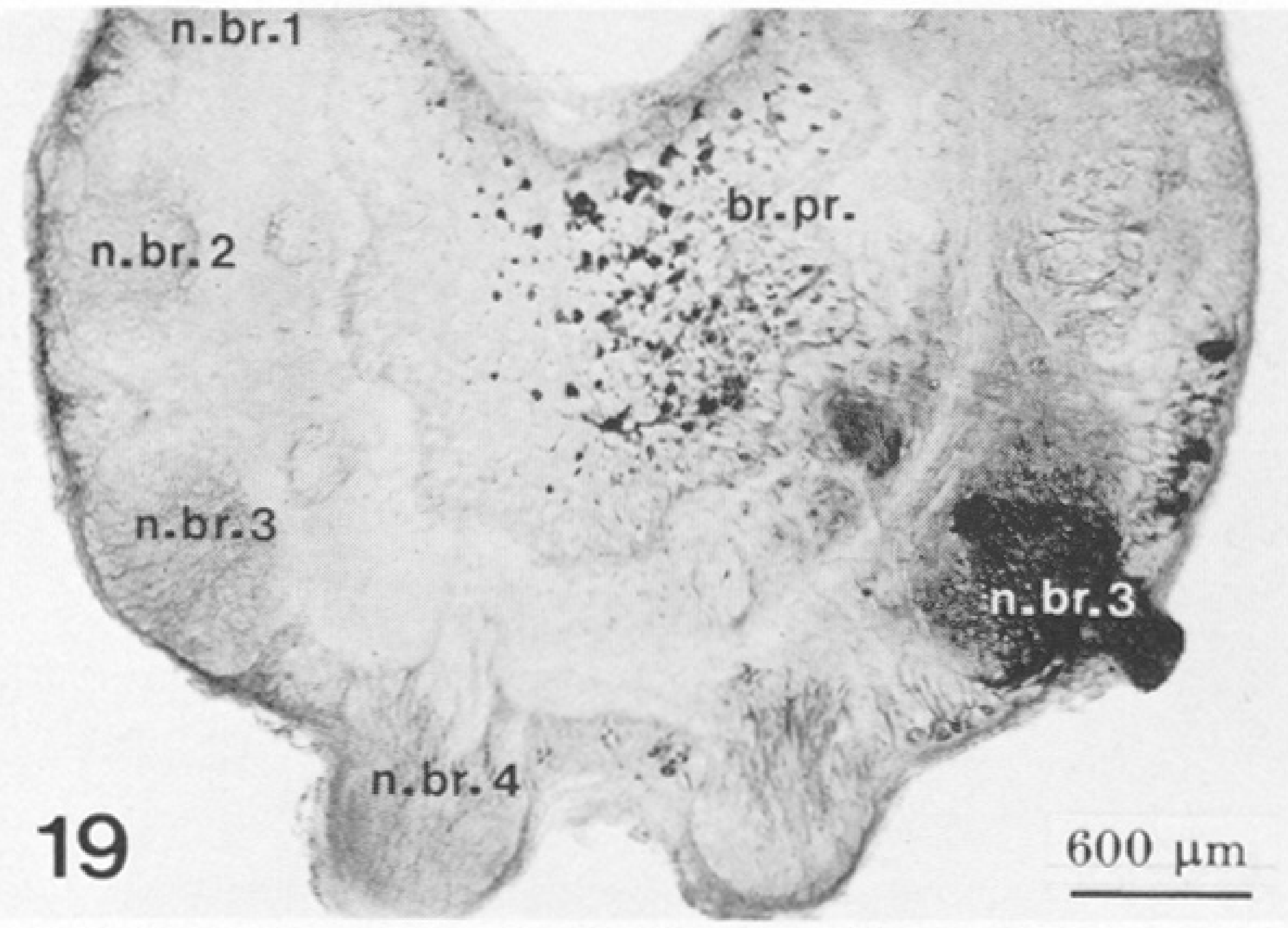

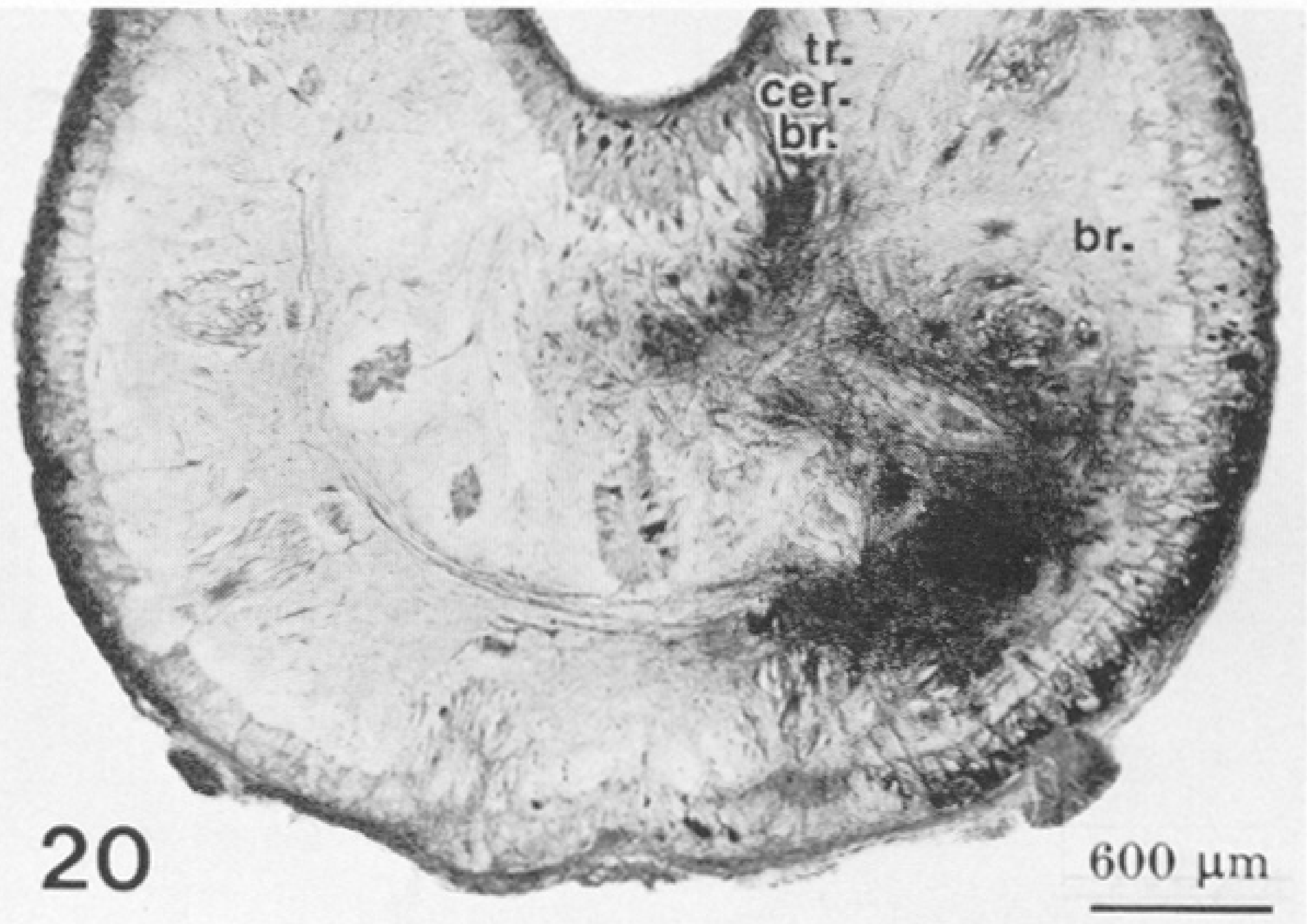

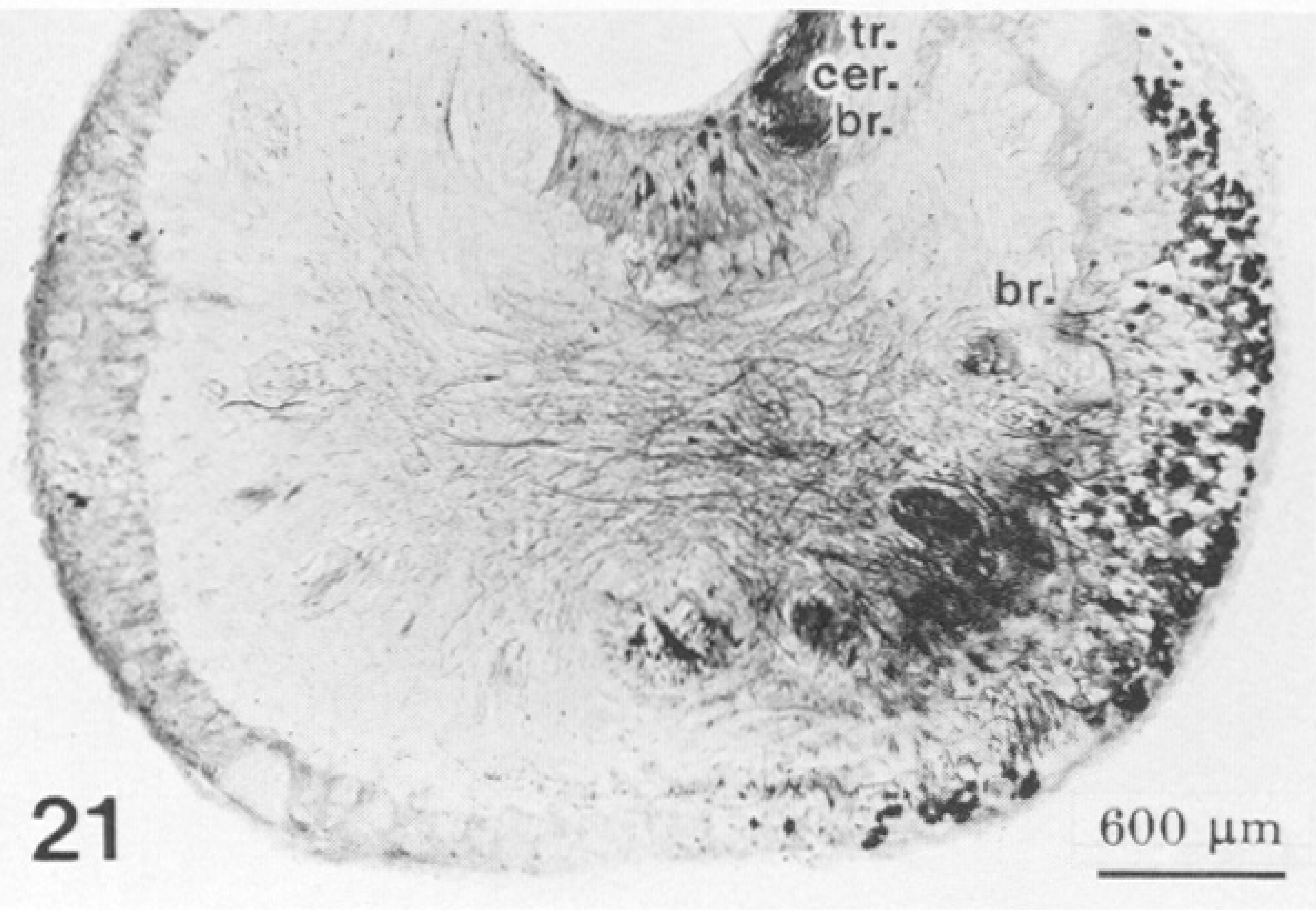

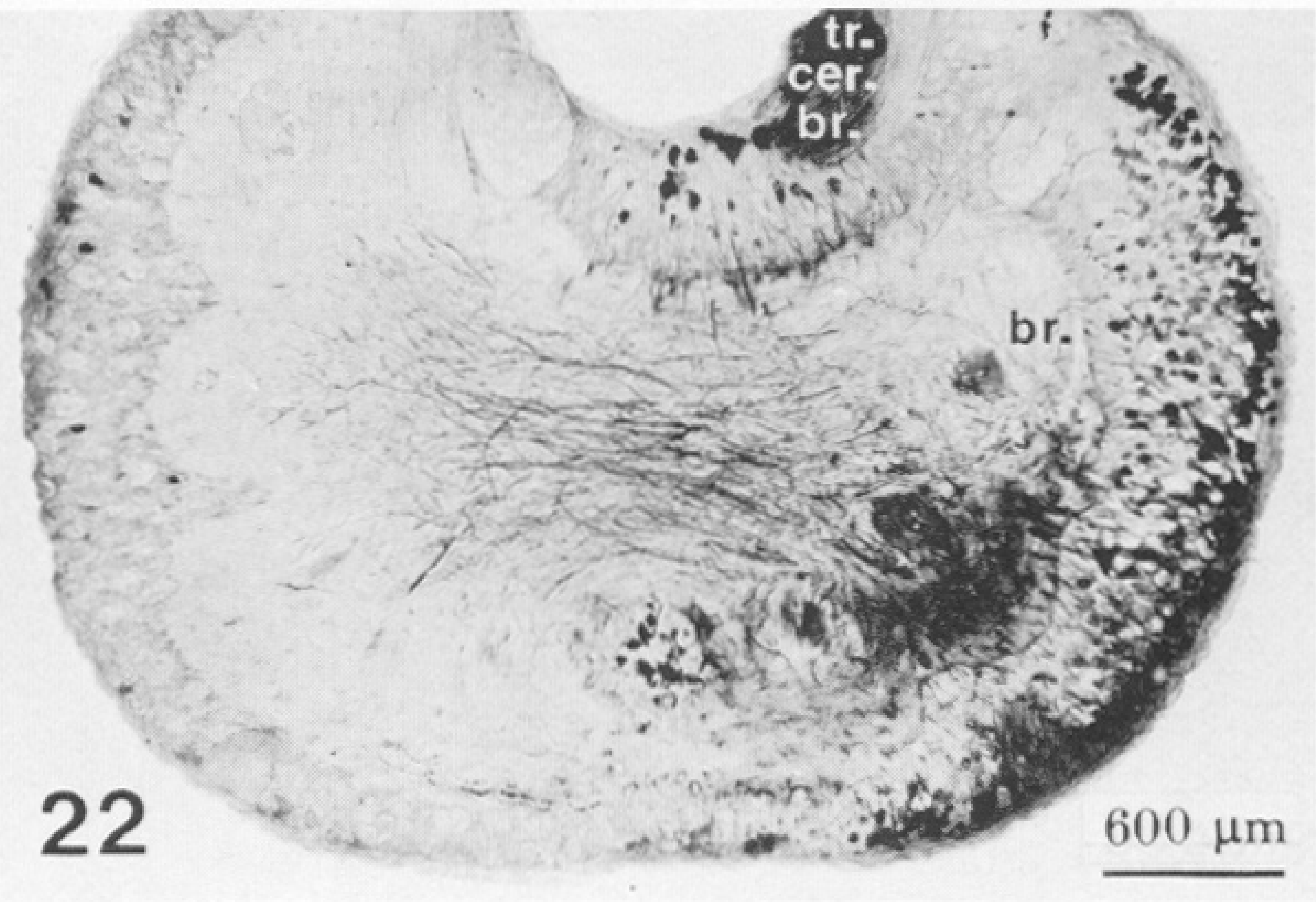

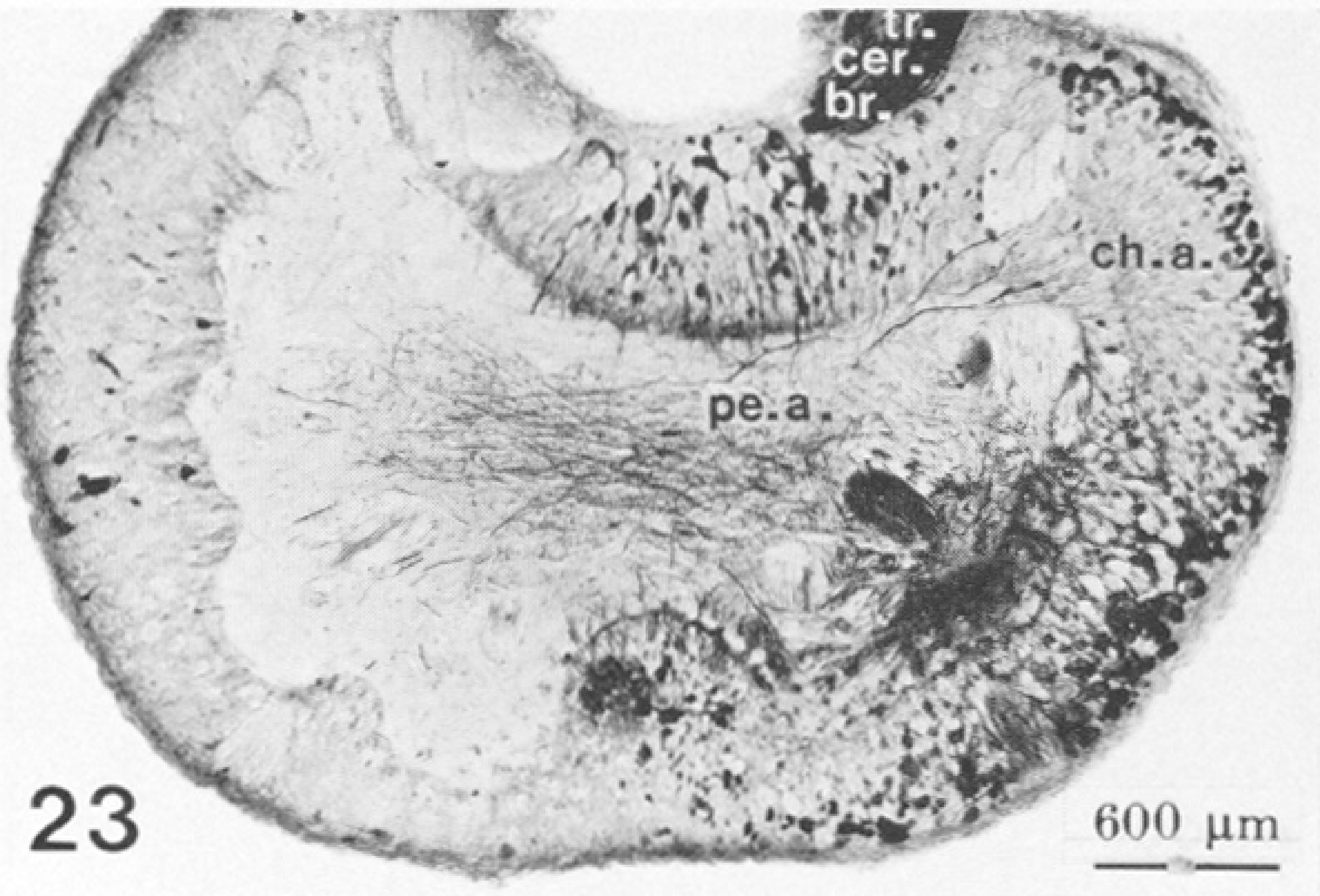

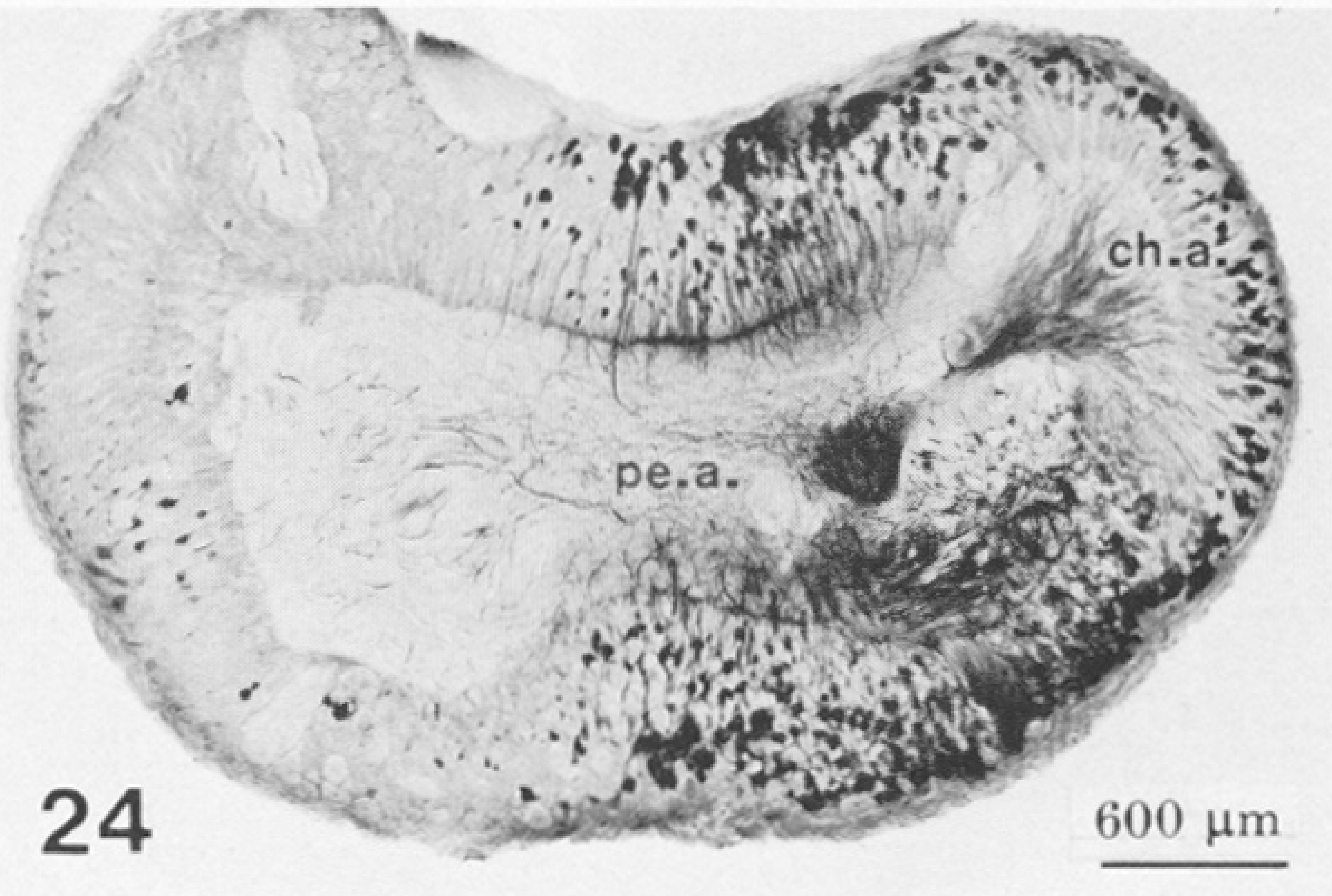

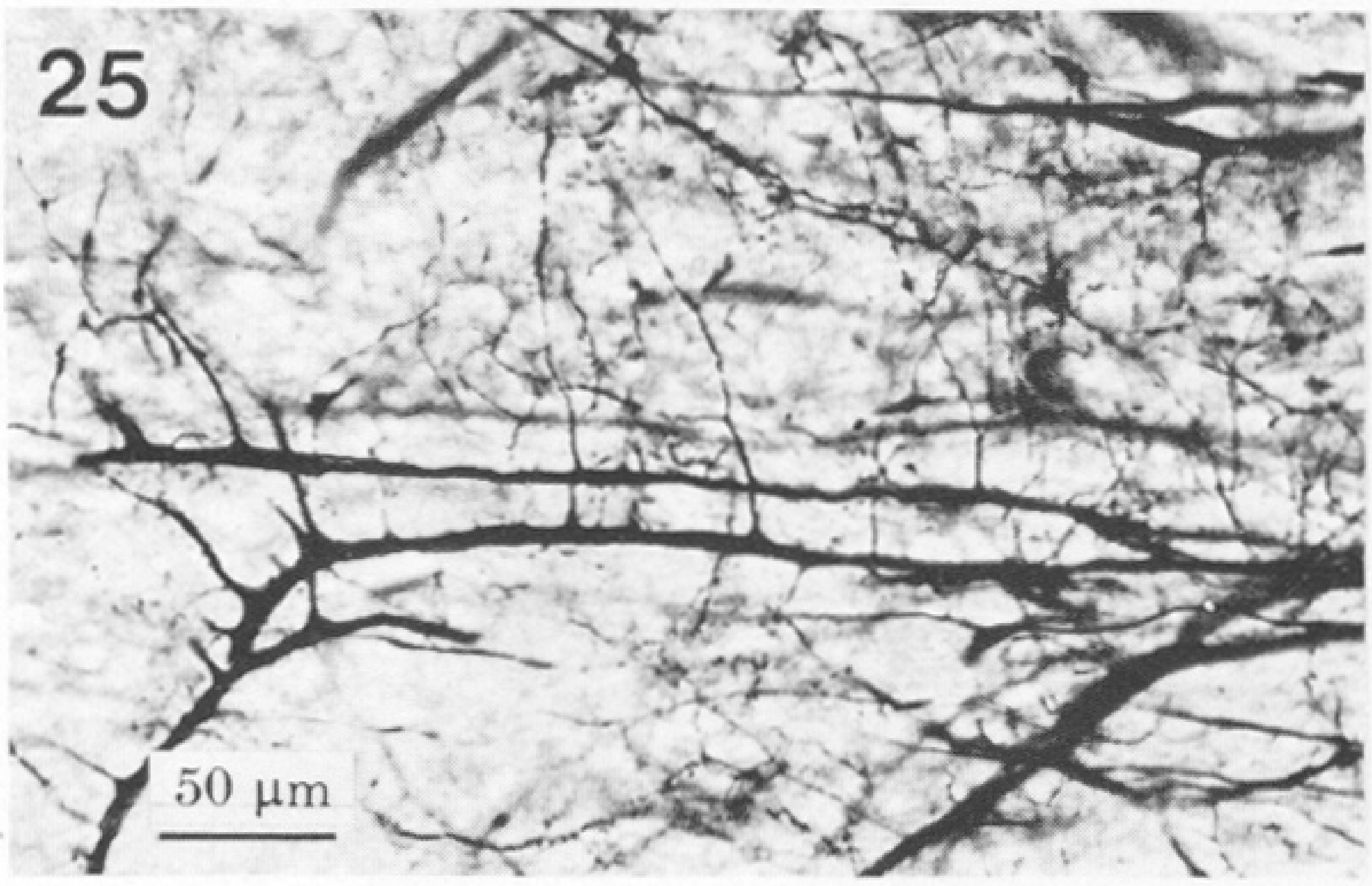

FIGURES 19–26. For description see opposite.

27

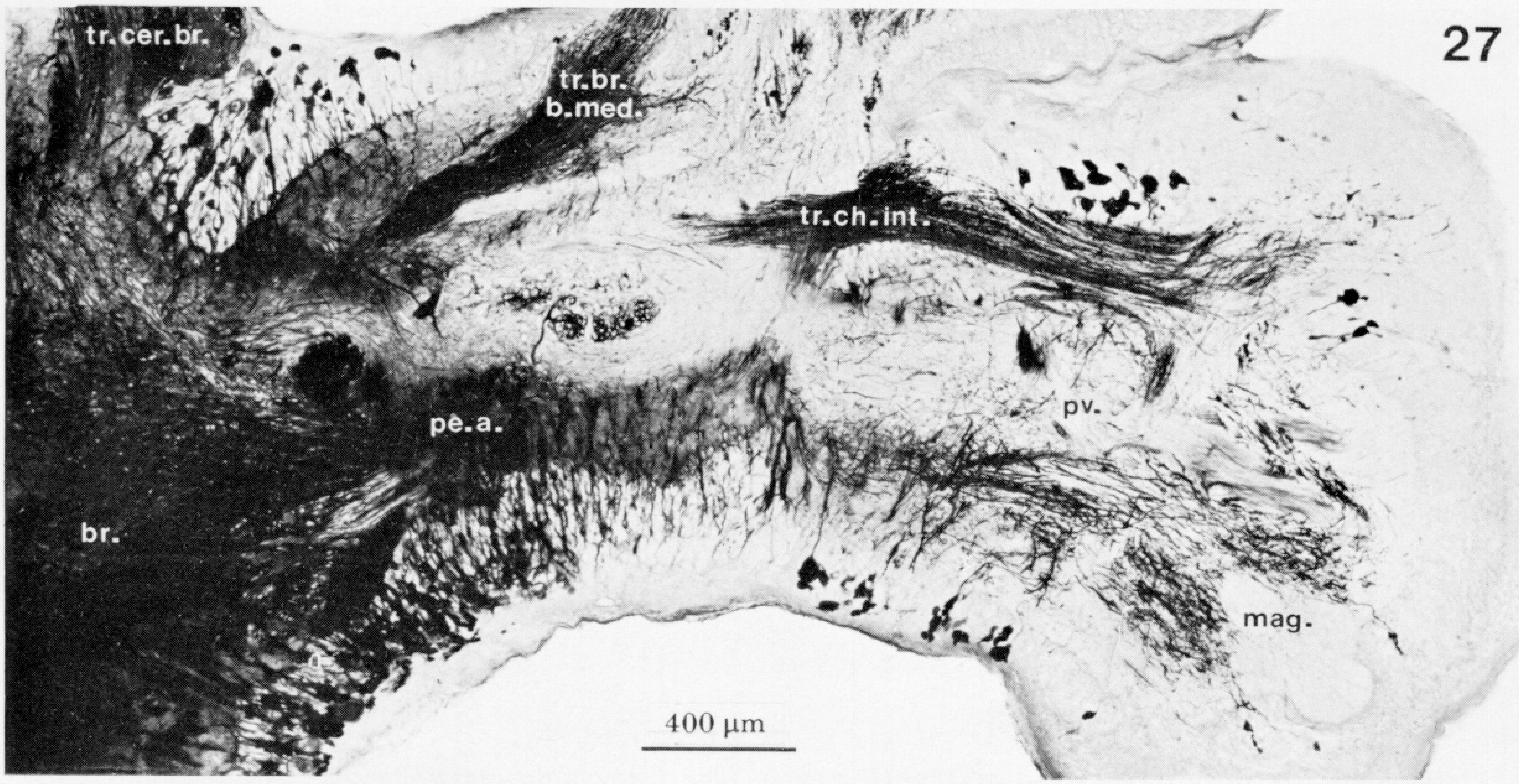

28

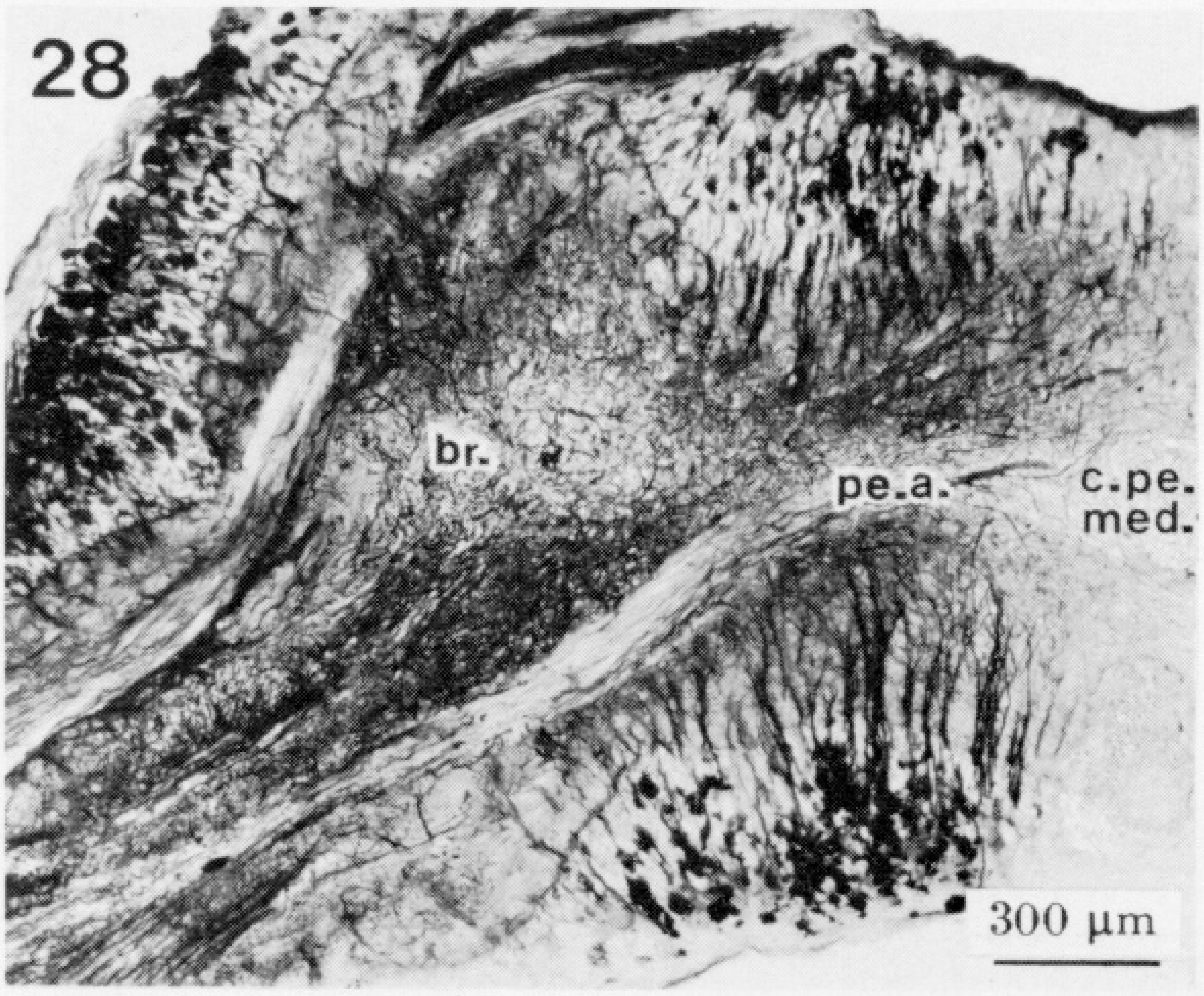

29

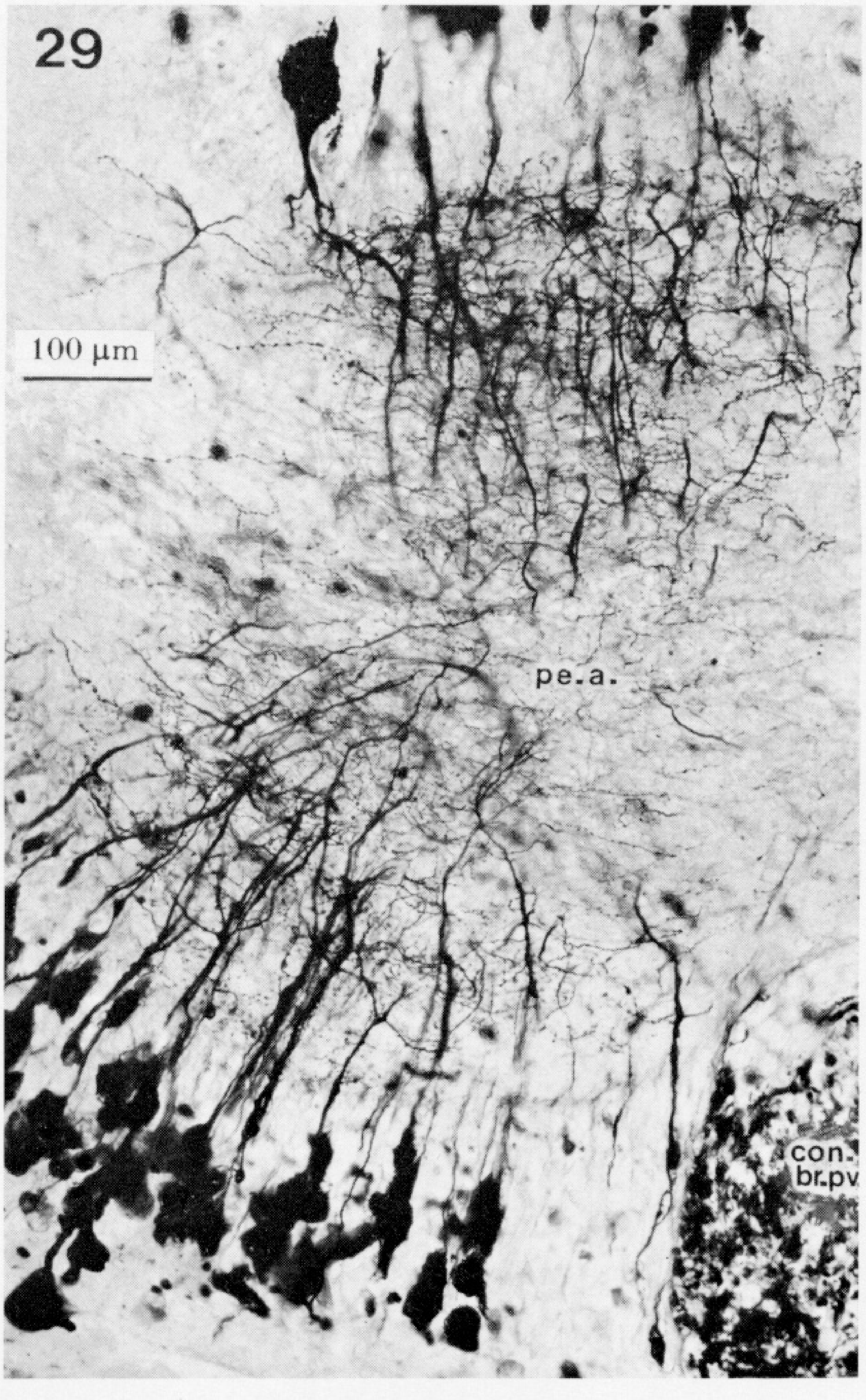

30

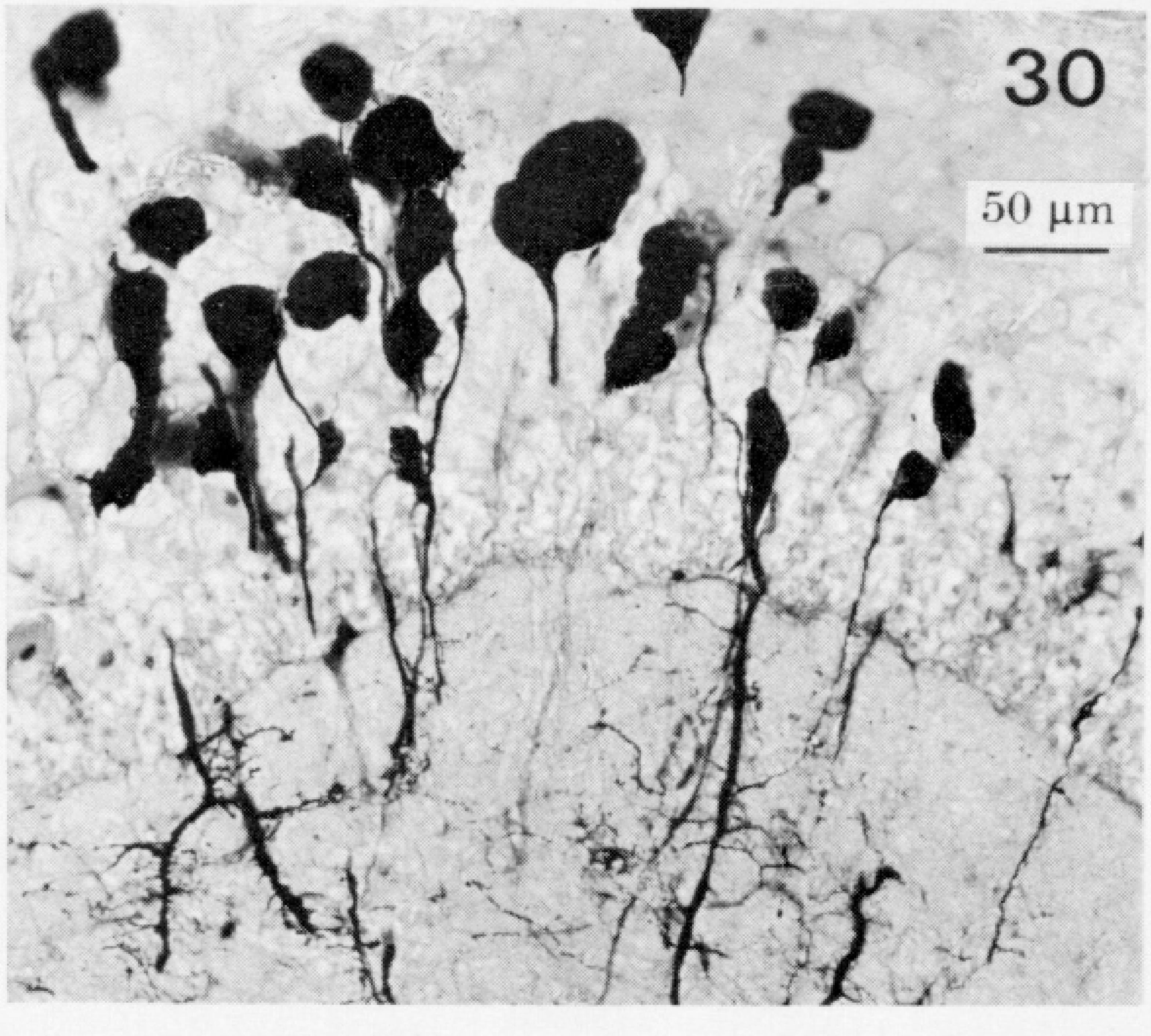

FIGURES 27–30. For description see opposite.

31

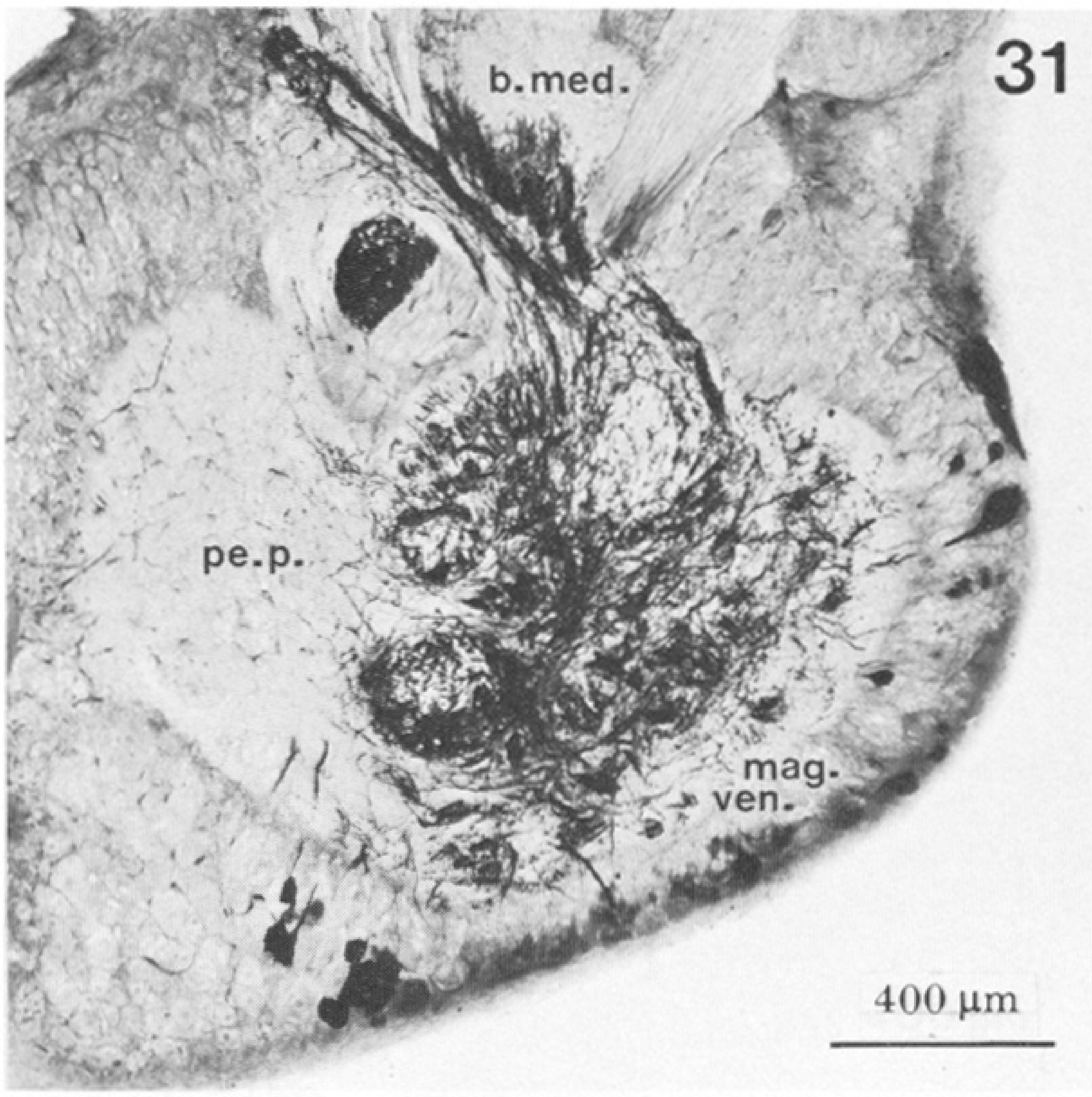

32

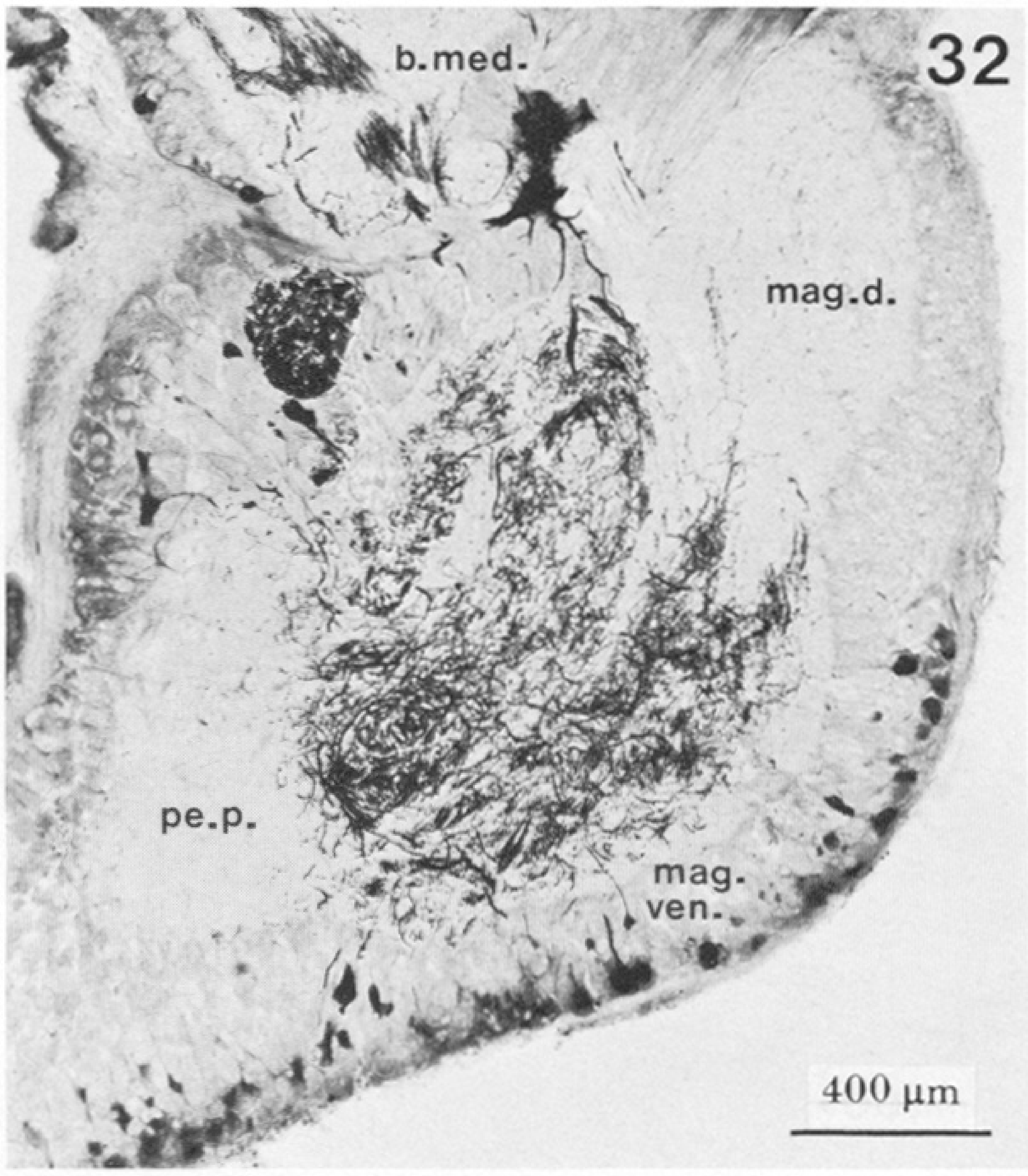

33

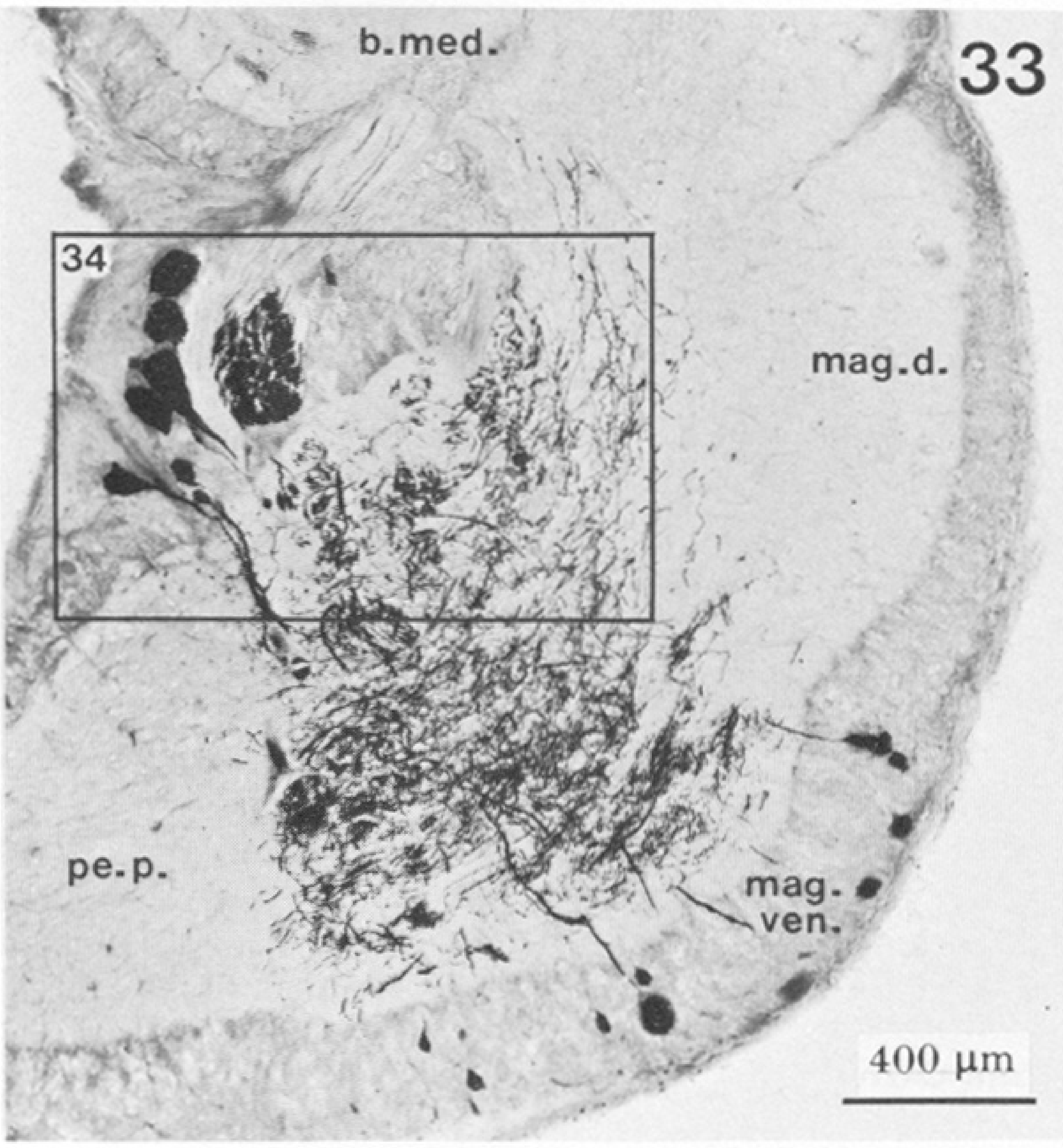

34

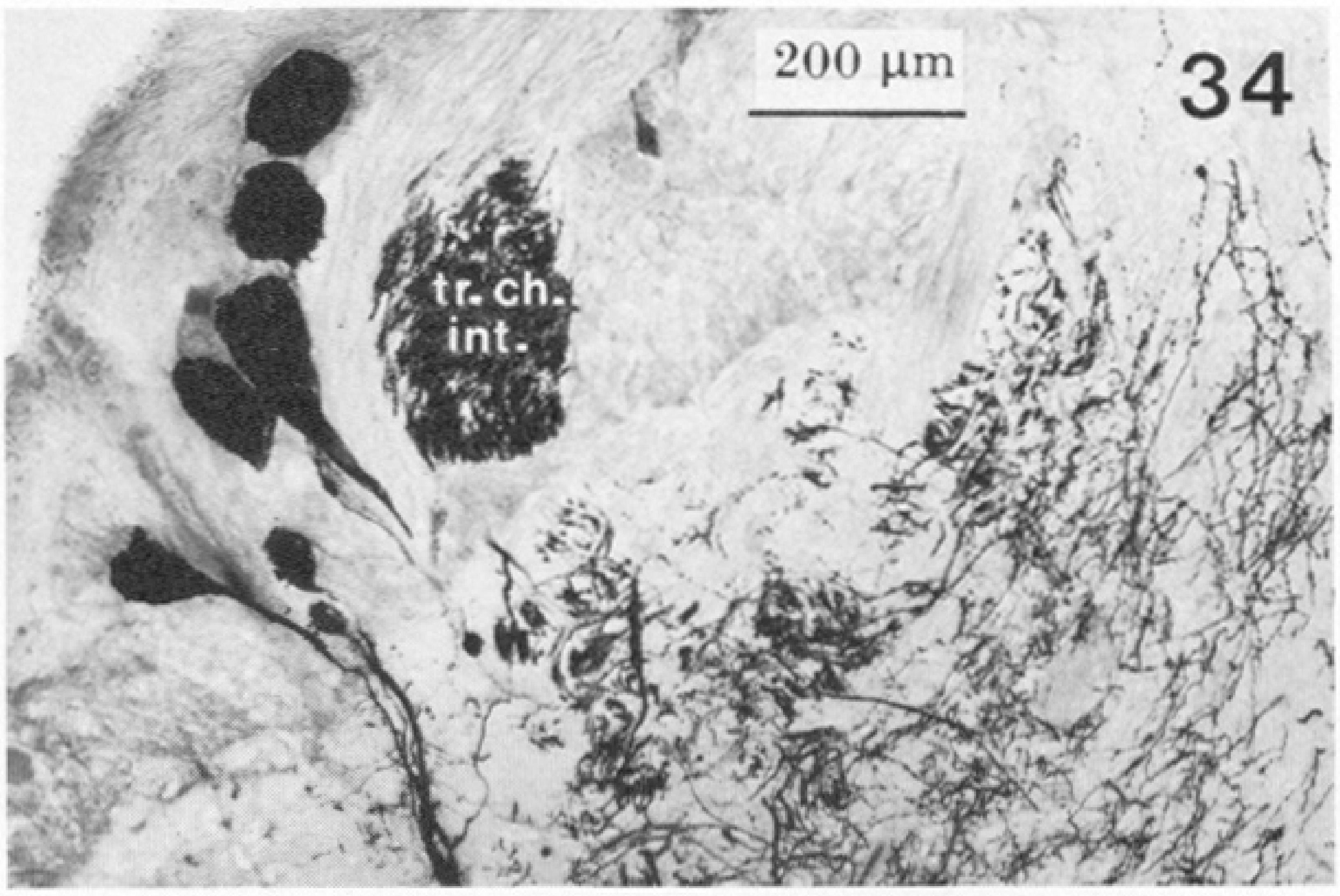

35

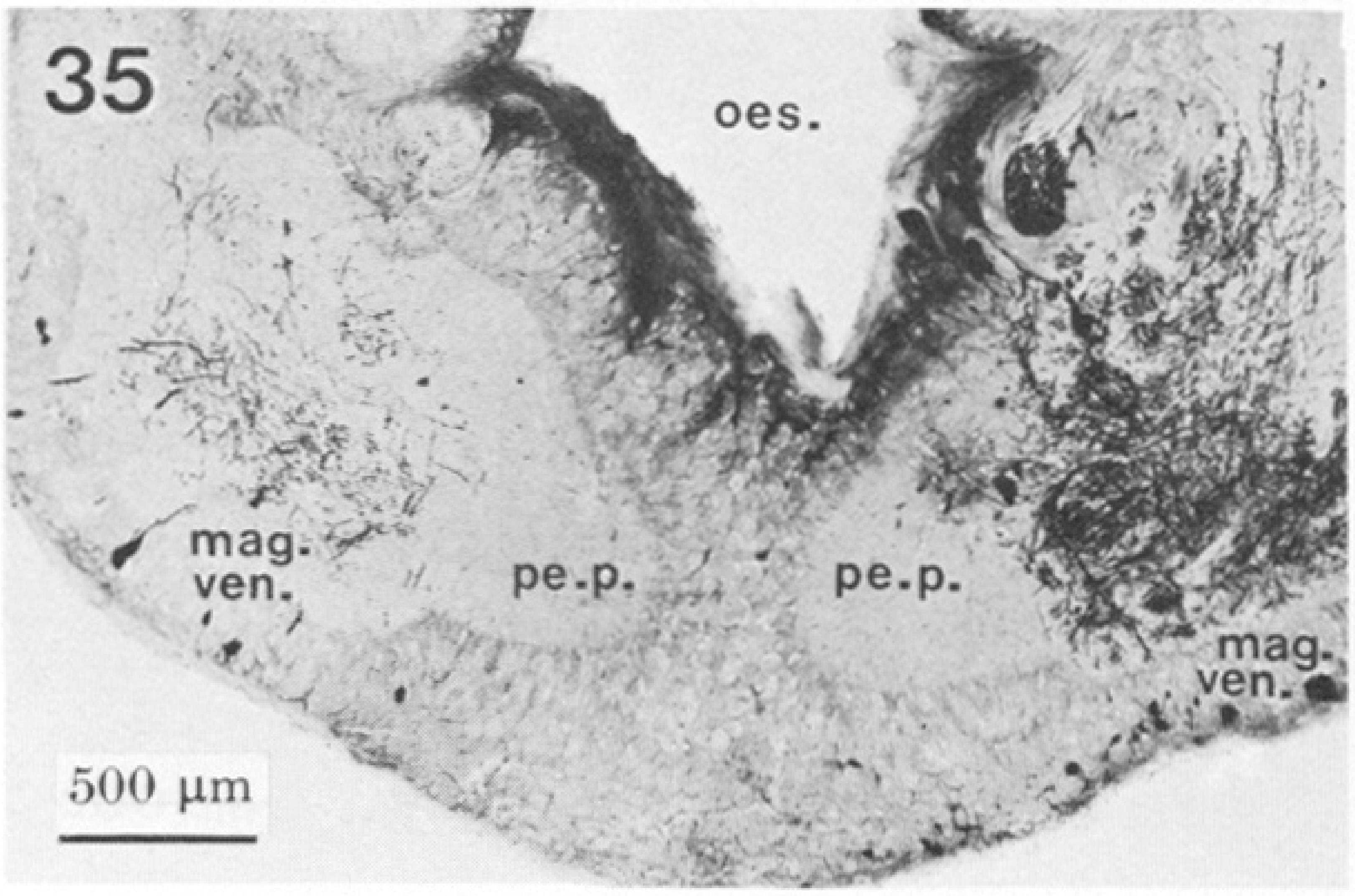

36

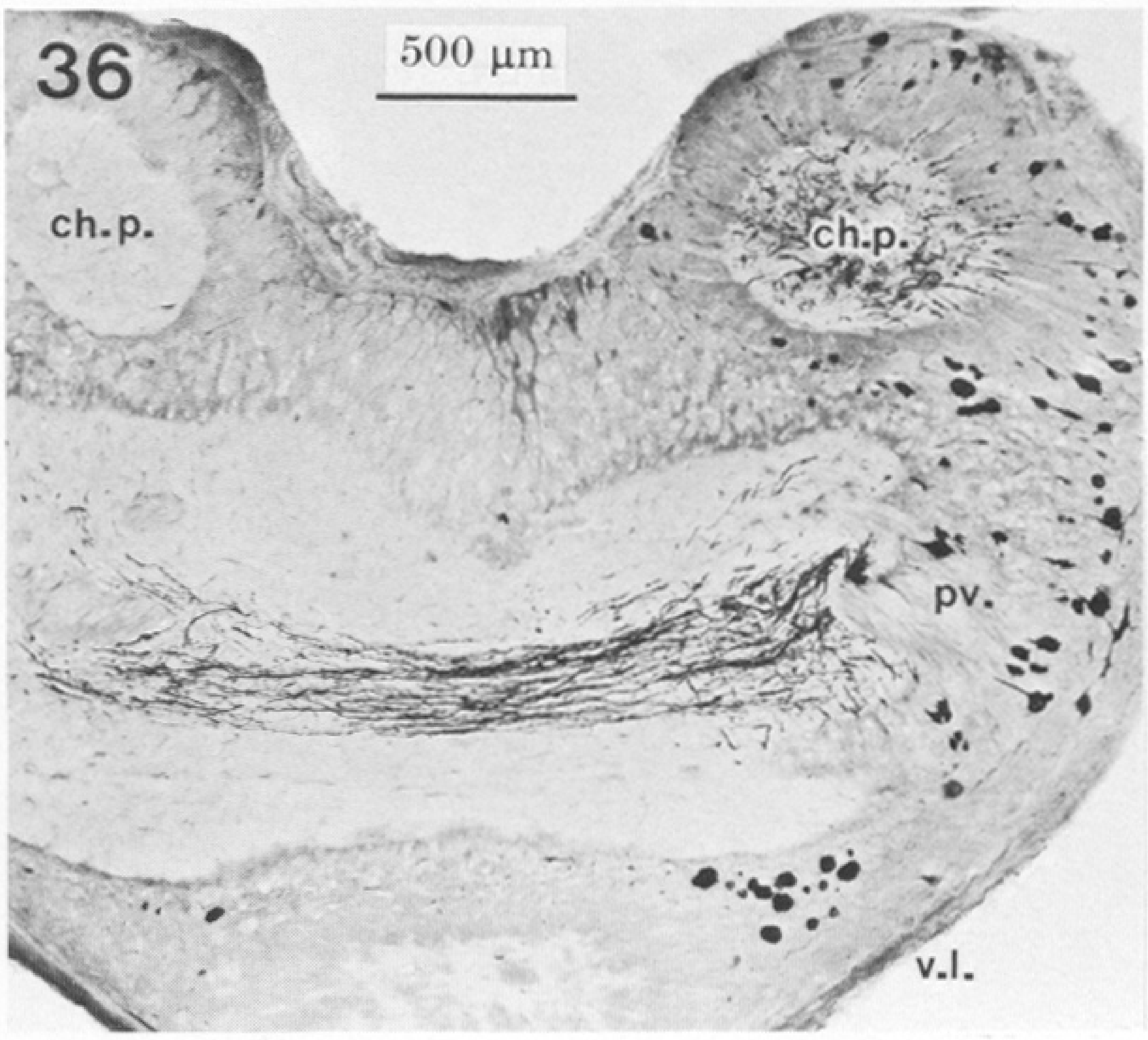

FIGURES 31–36. For description see opposite.

37

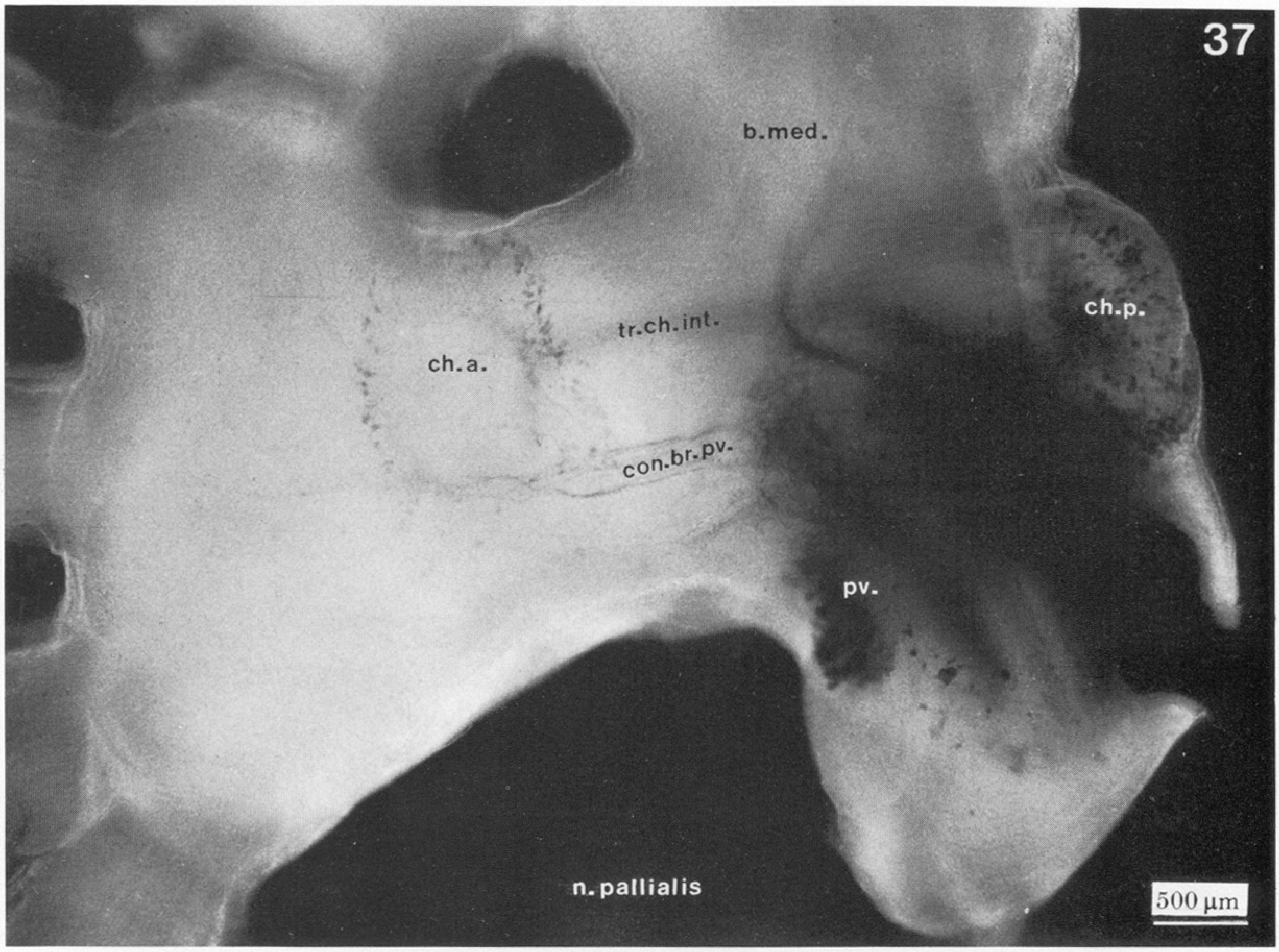

38

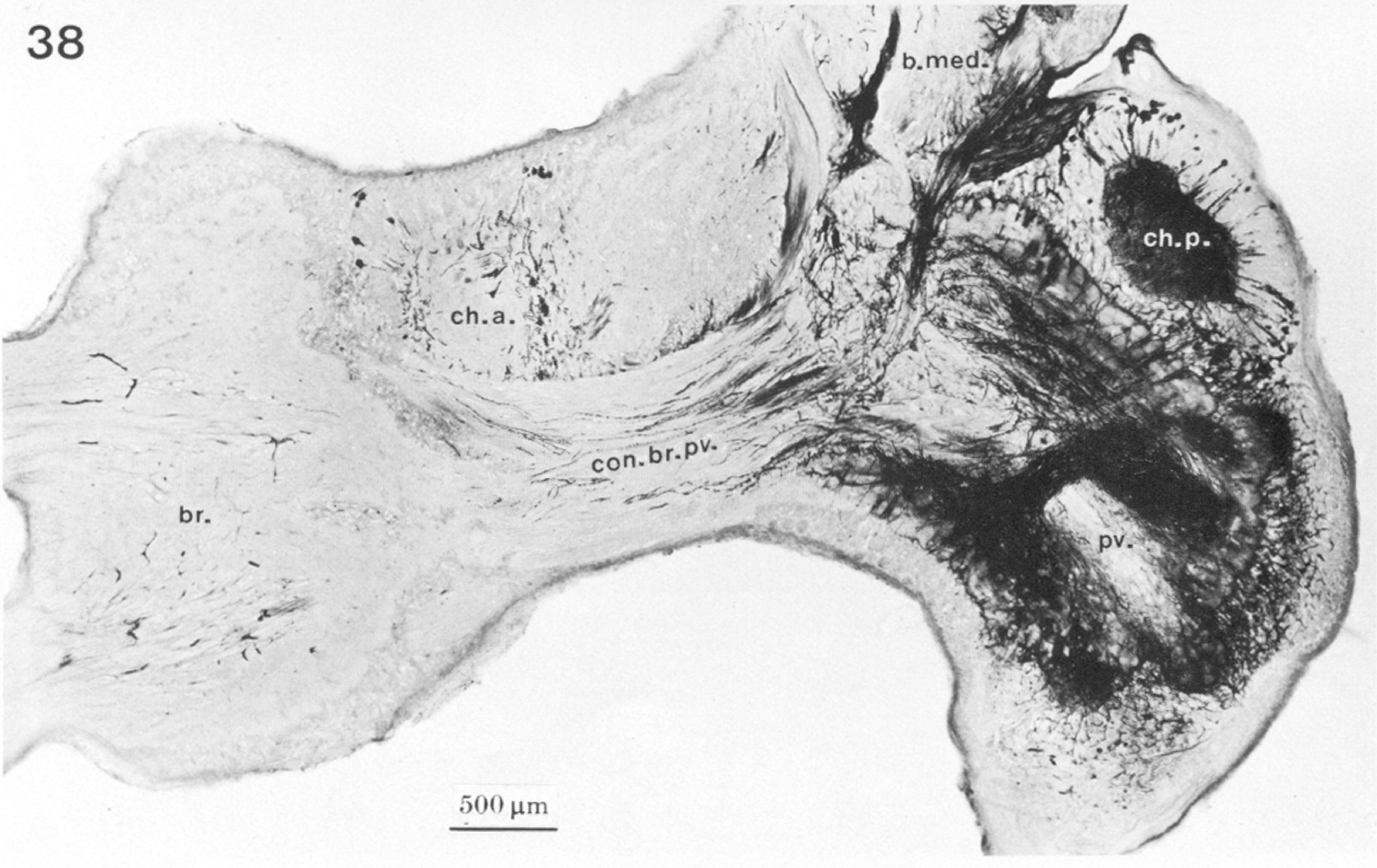

FIGURES 37 AND 38. For description see opposite:

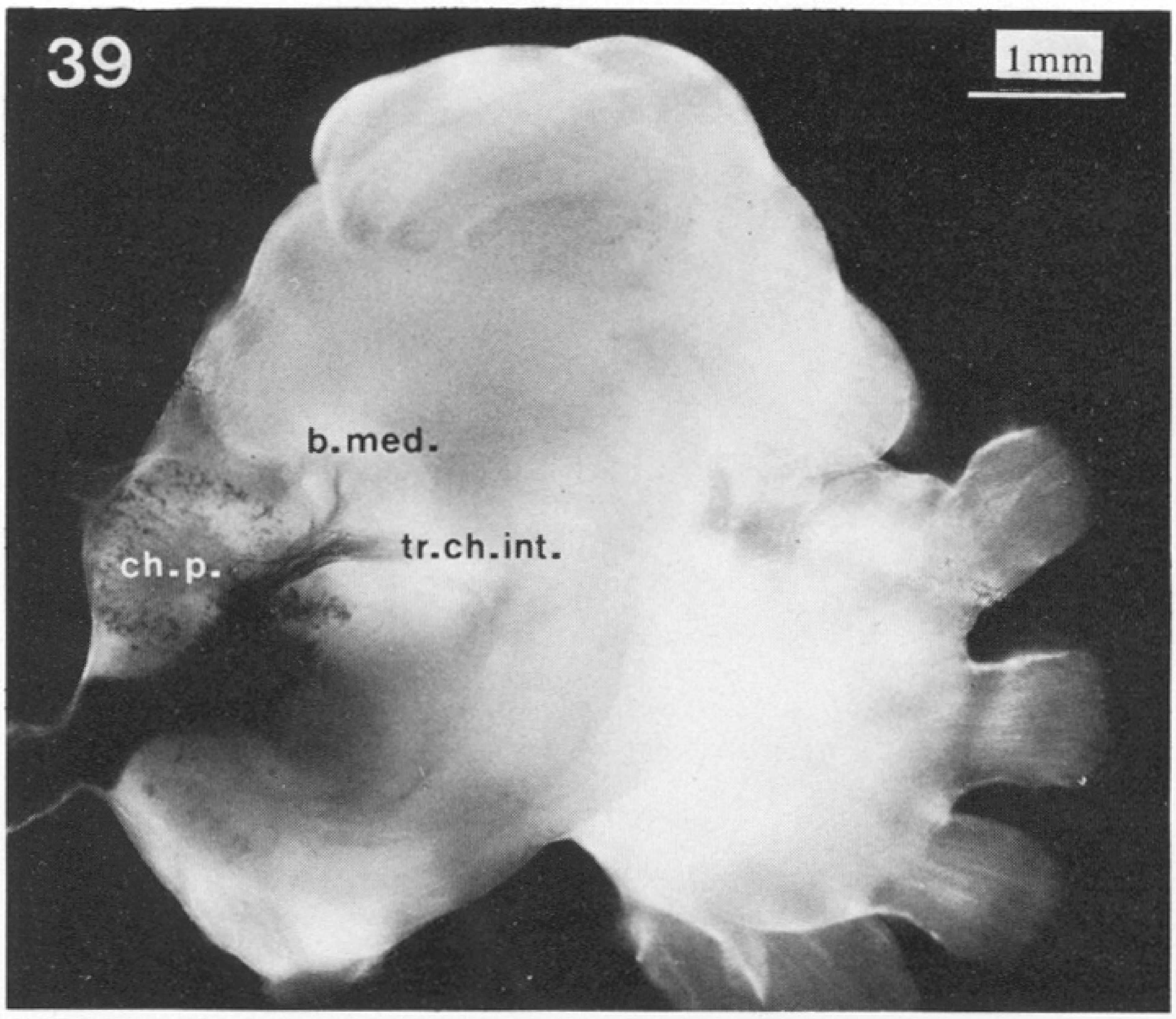

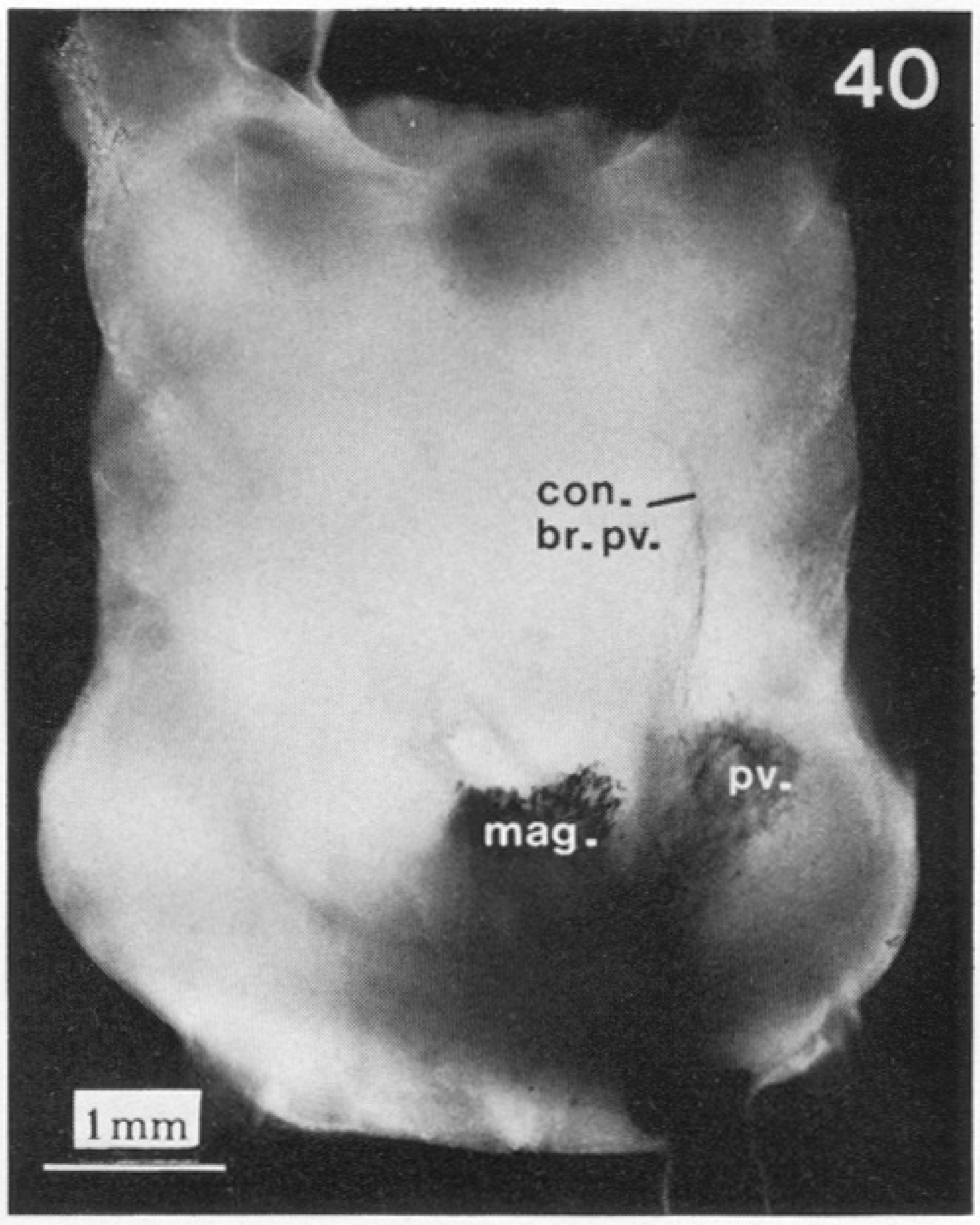

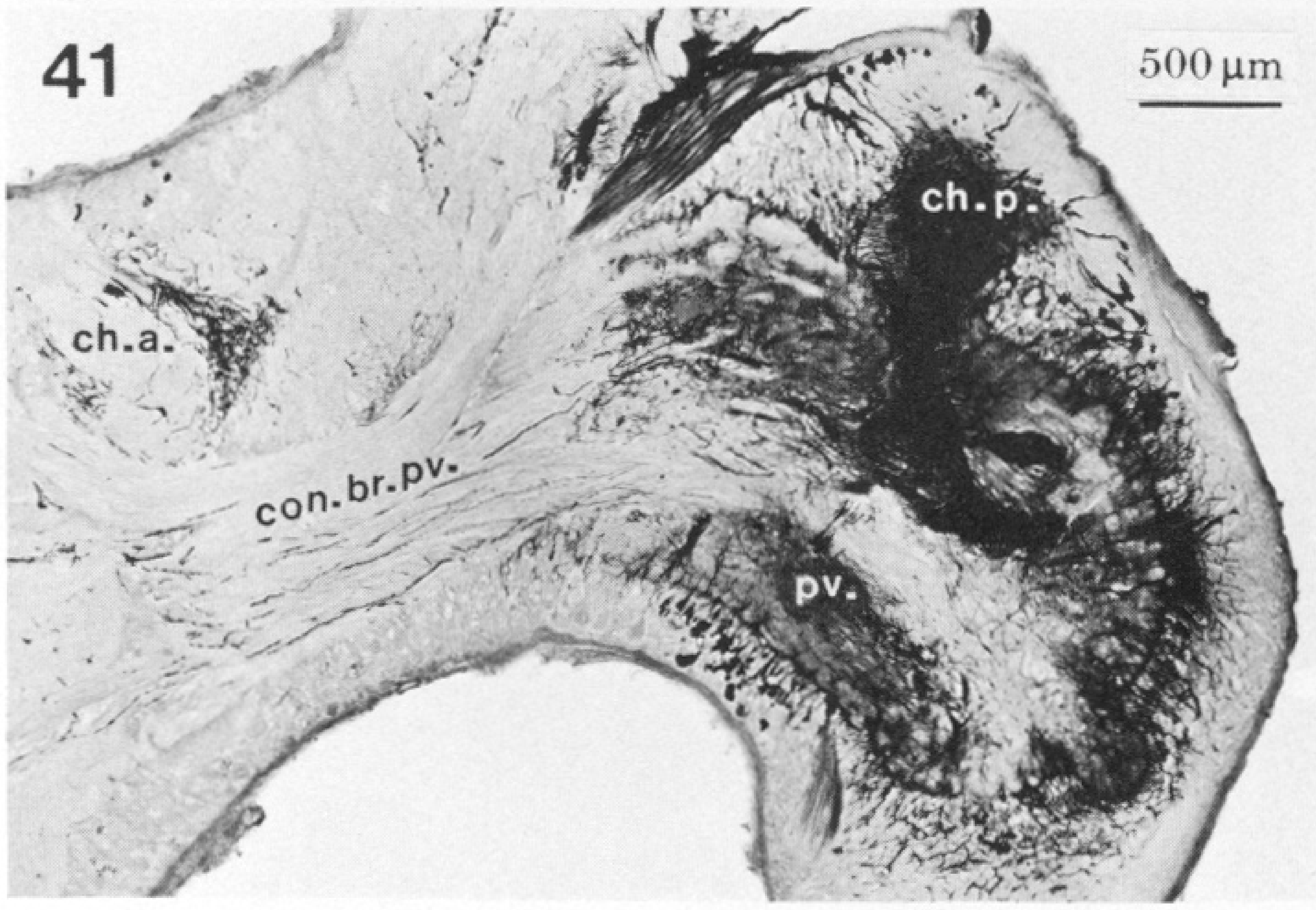

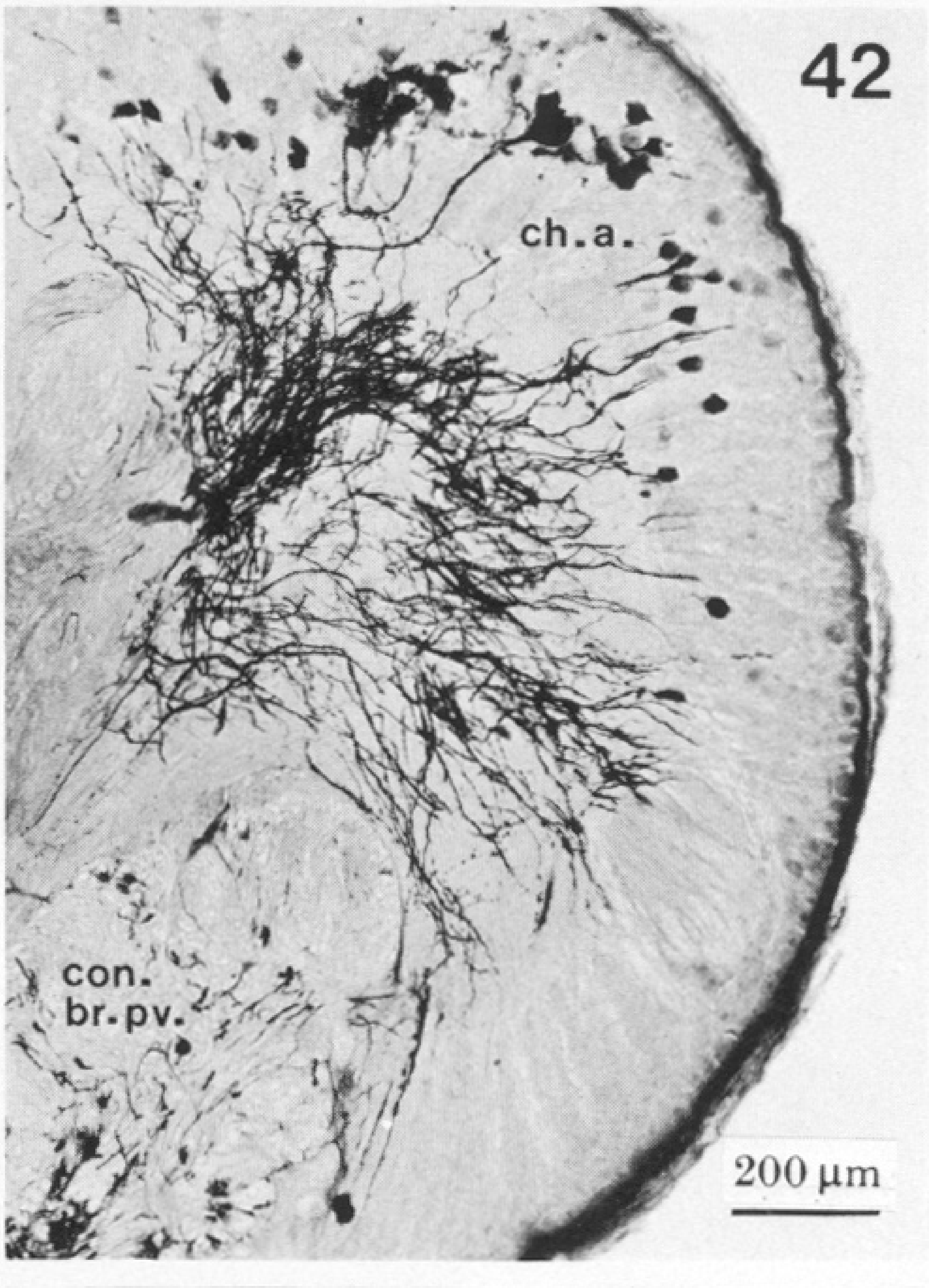

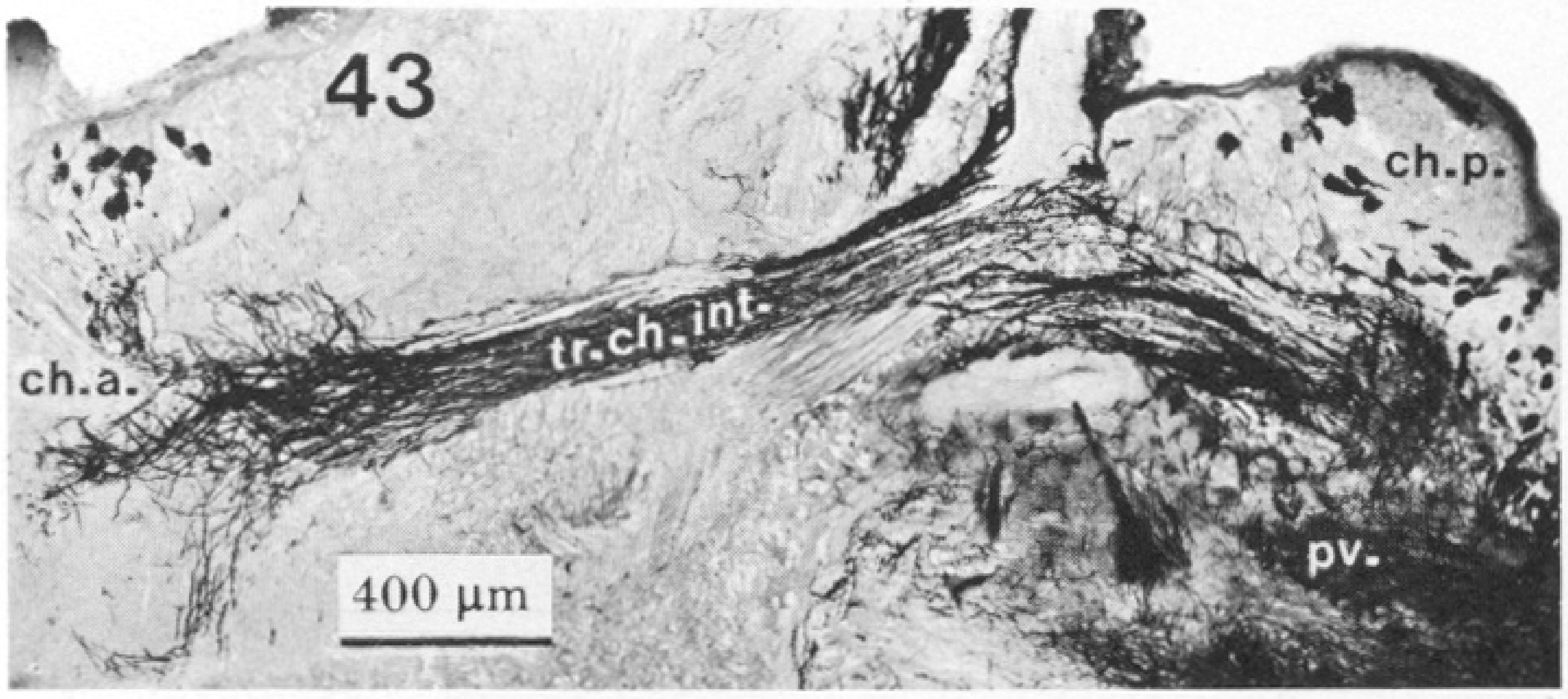

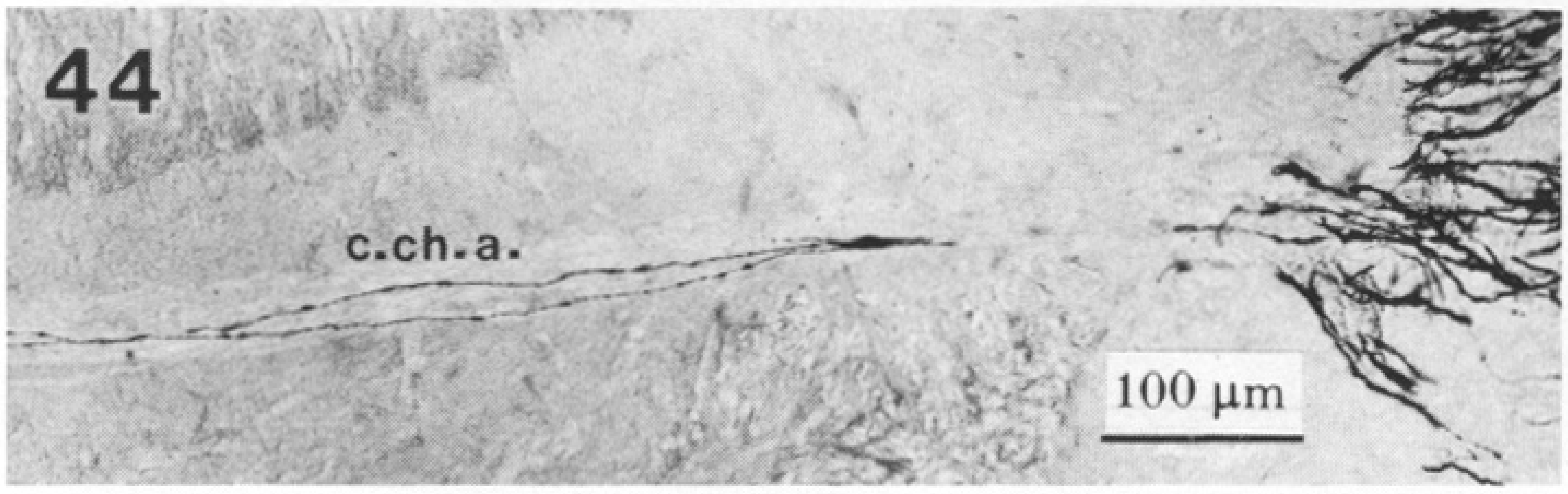

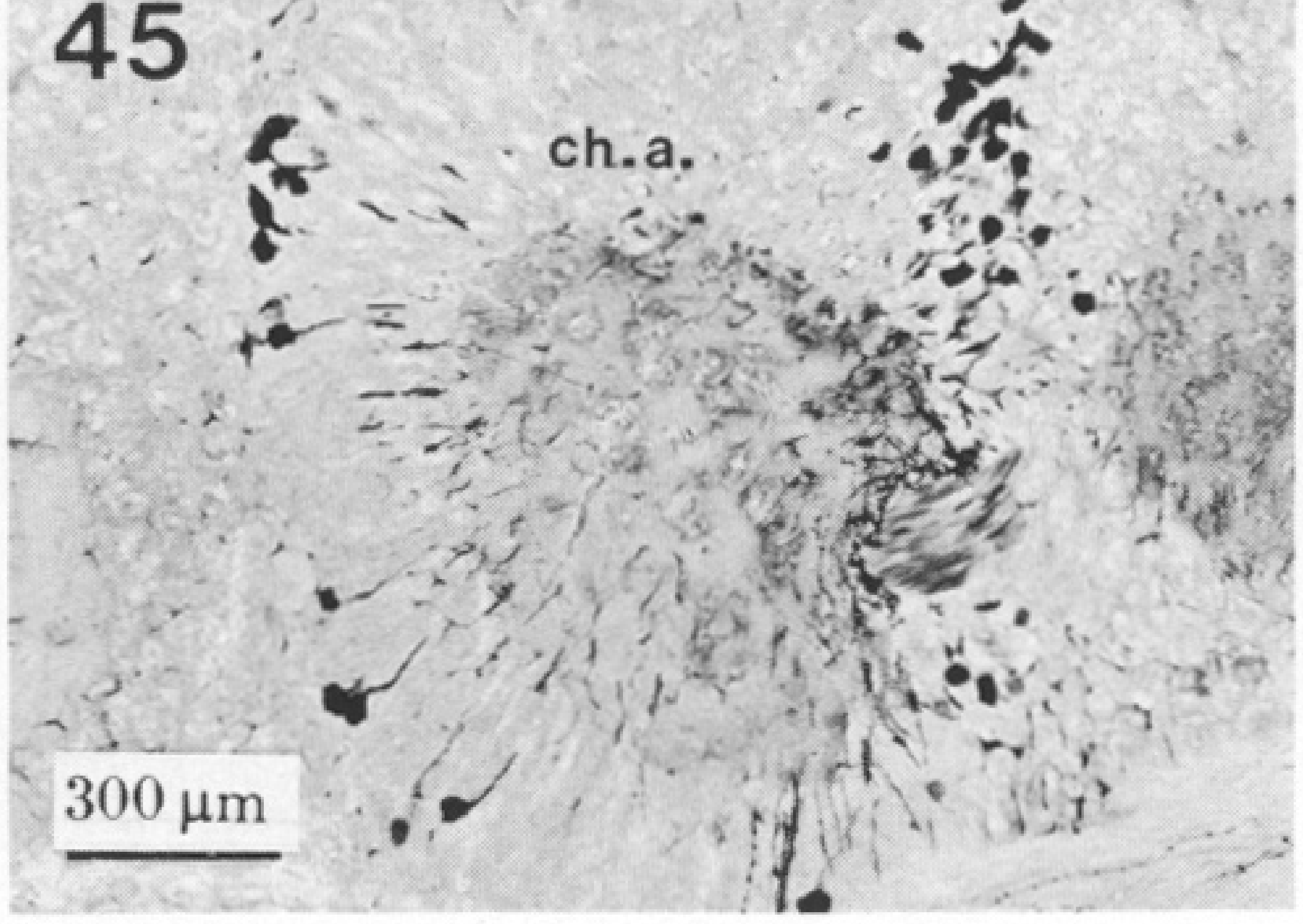

FIGURES 39–45. For description see p. 116.

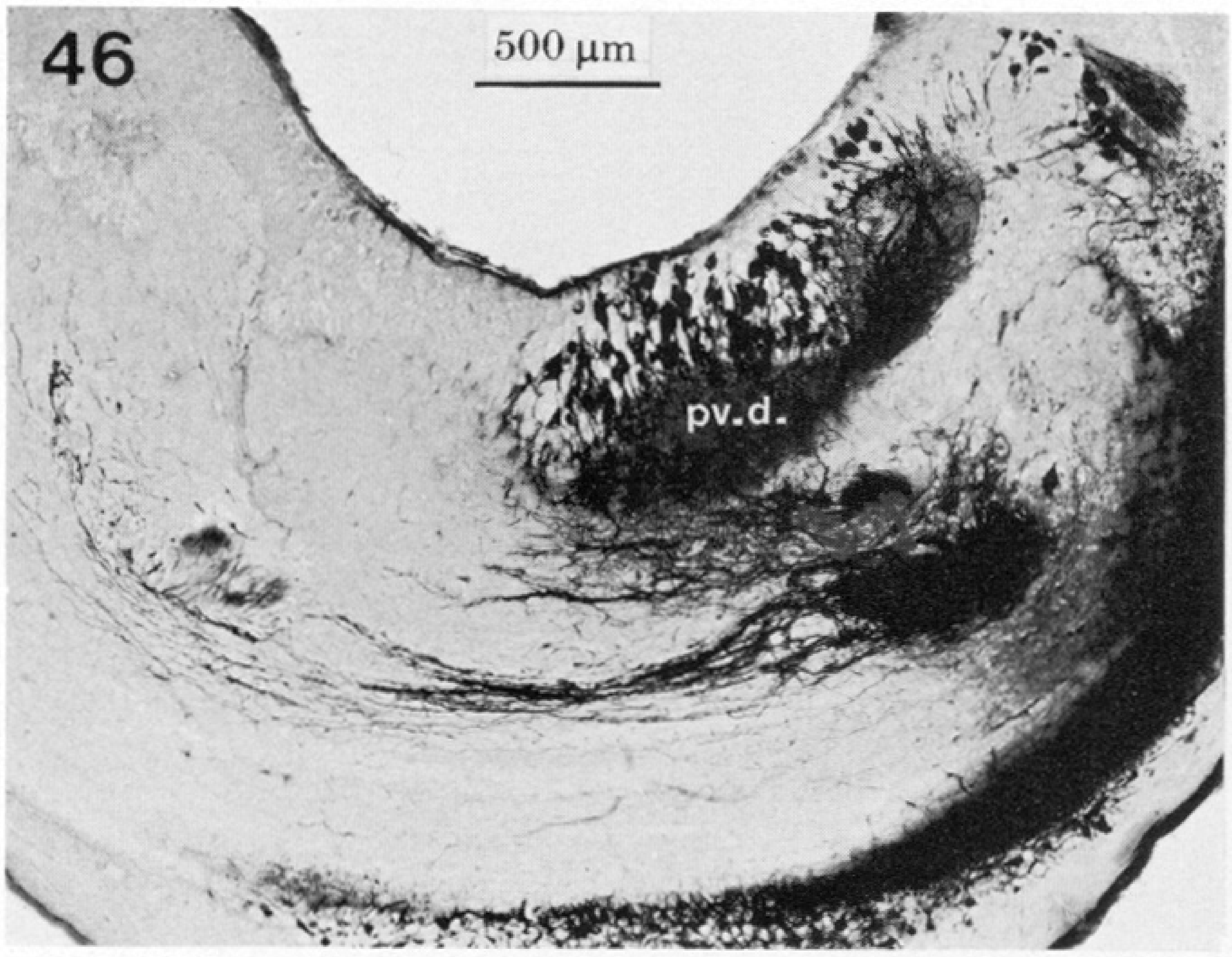



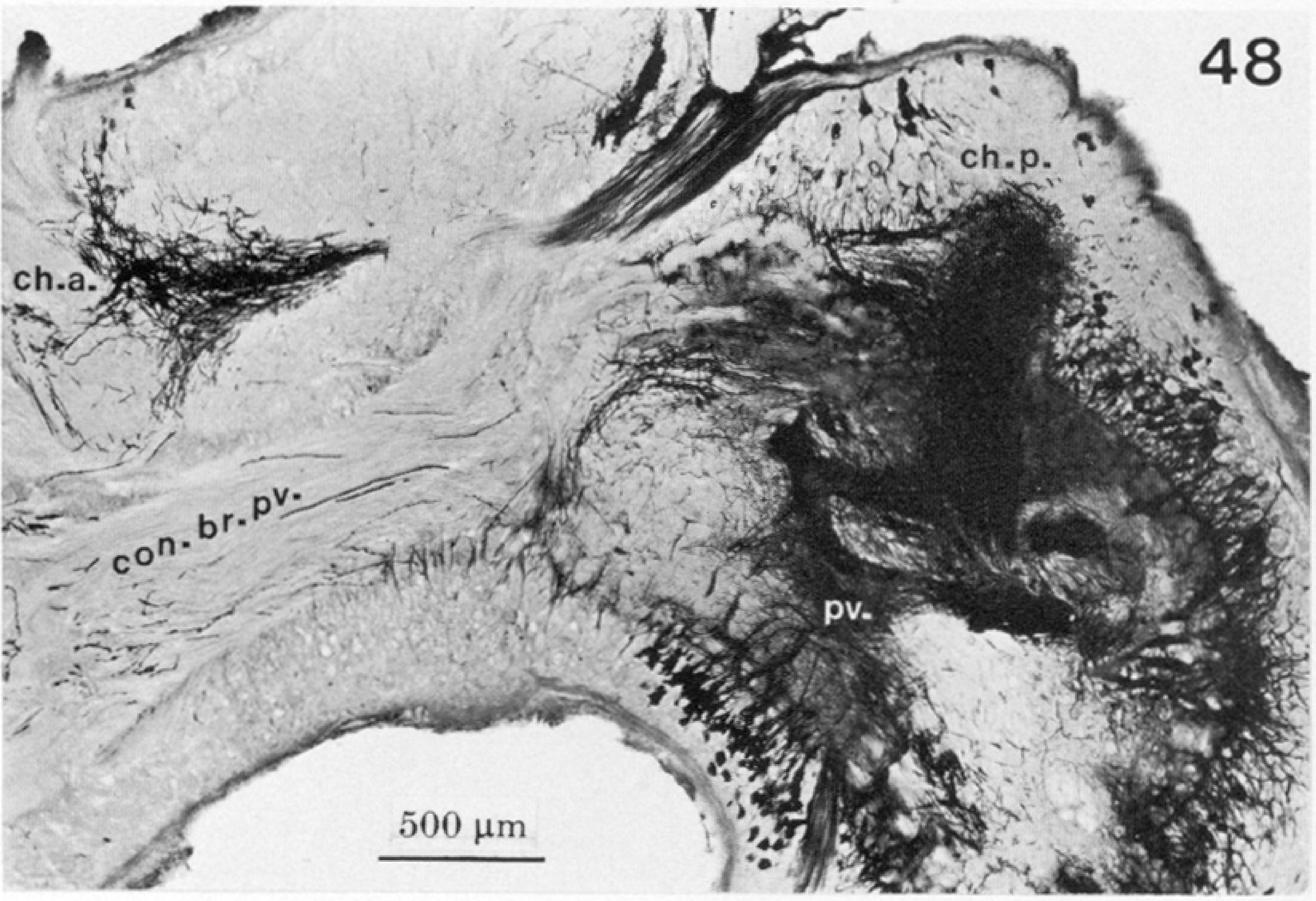

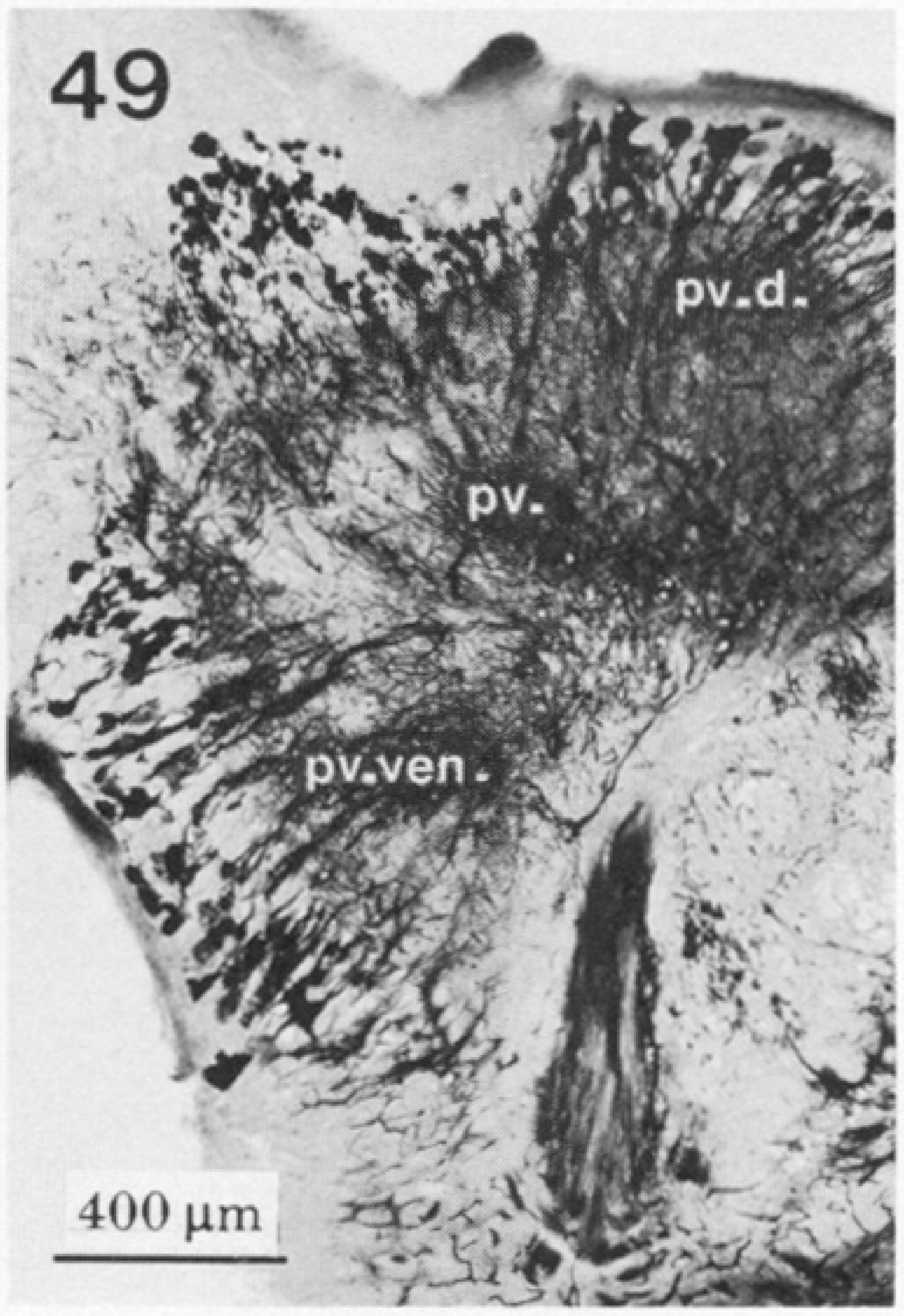

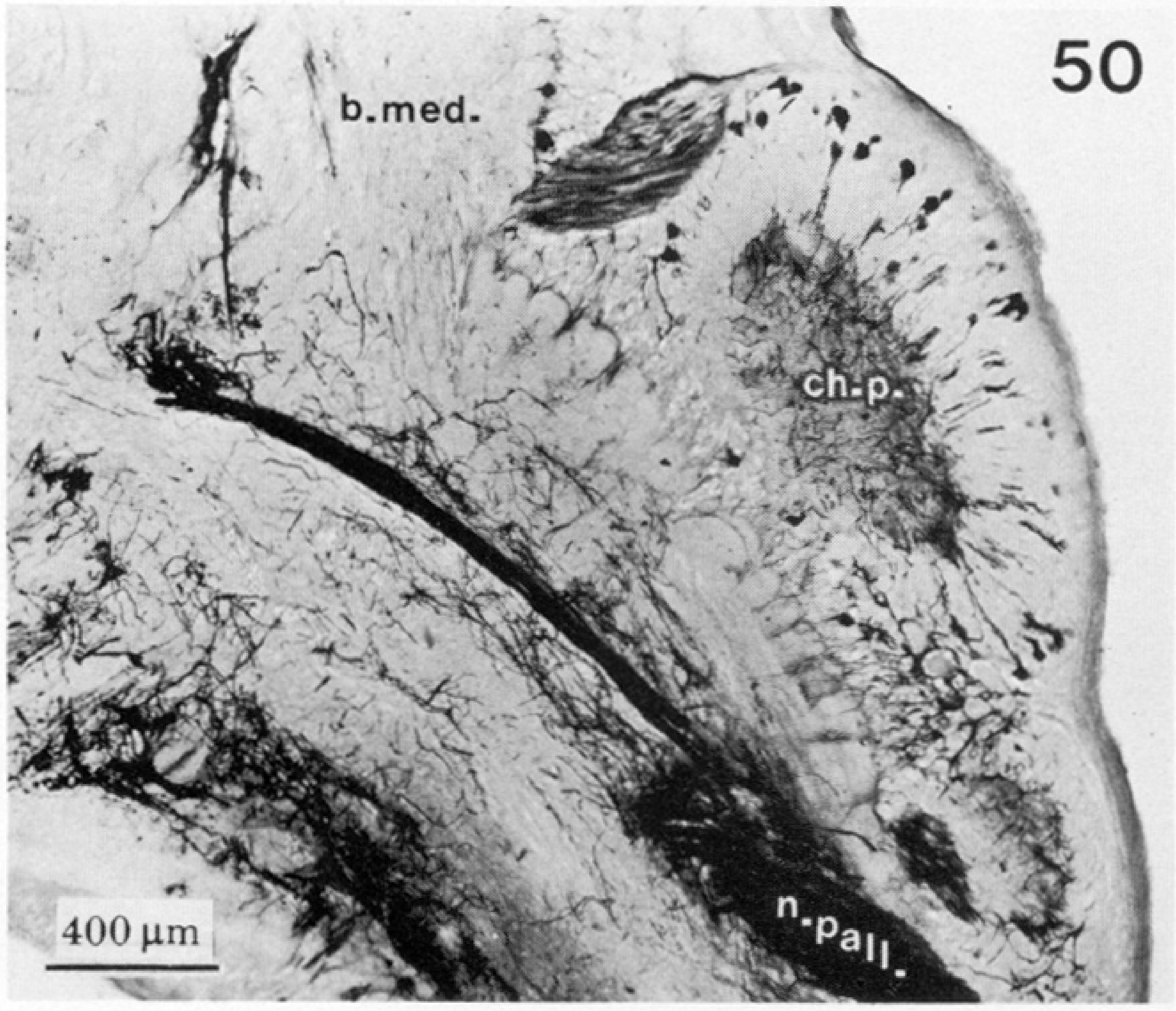

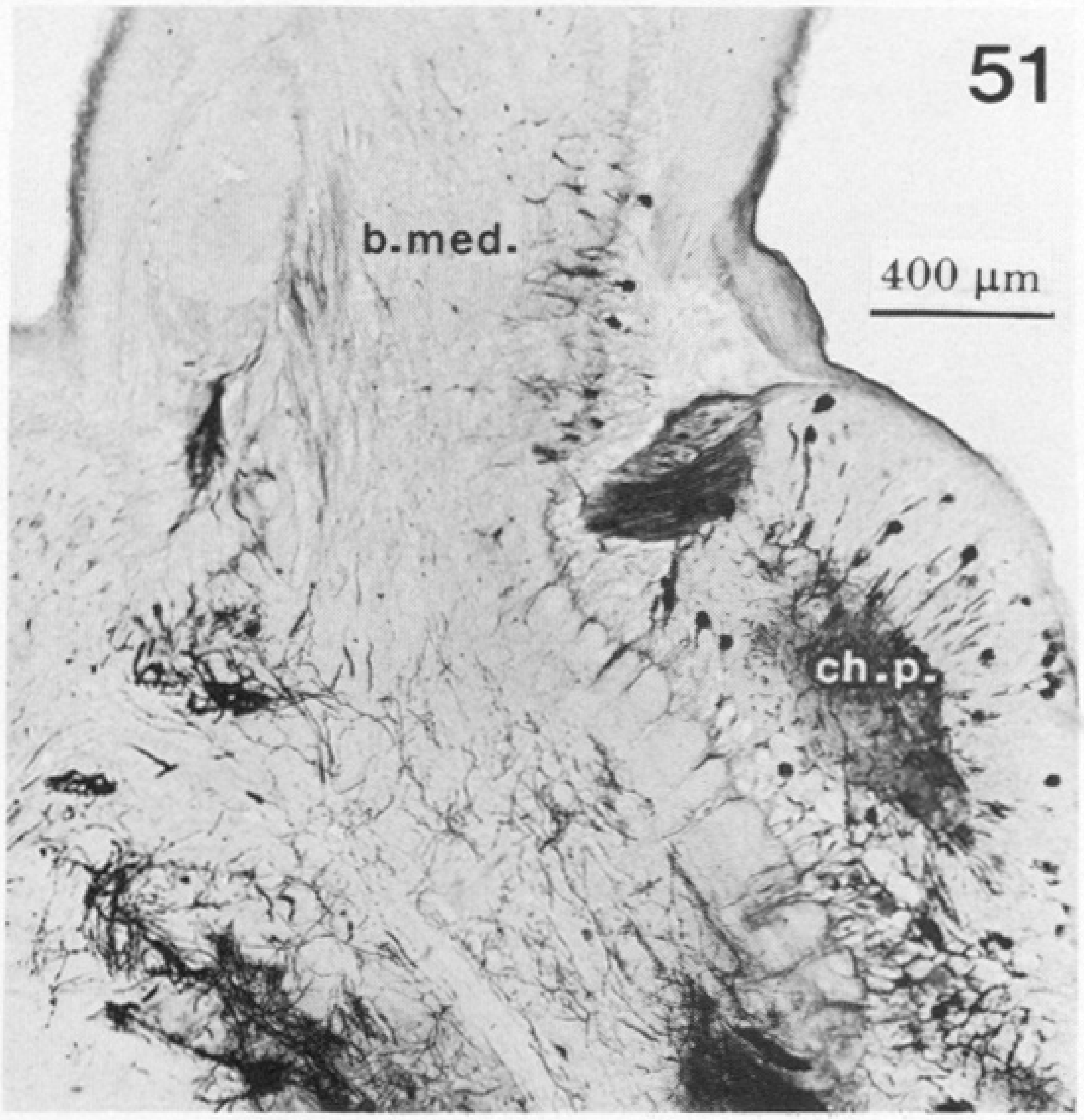

FIGURES 46–51. For description see p. 117.

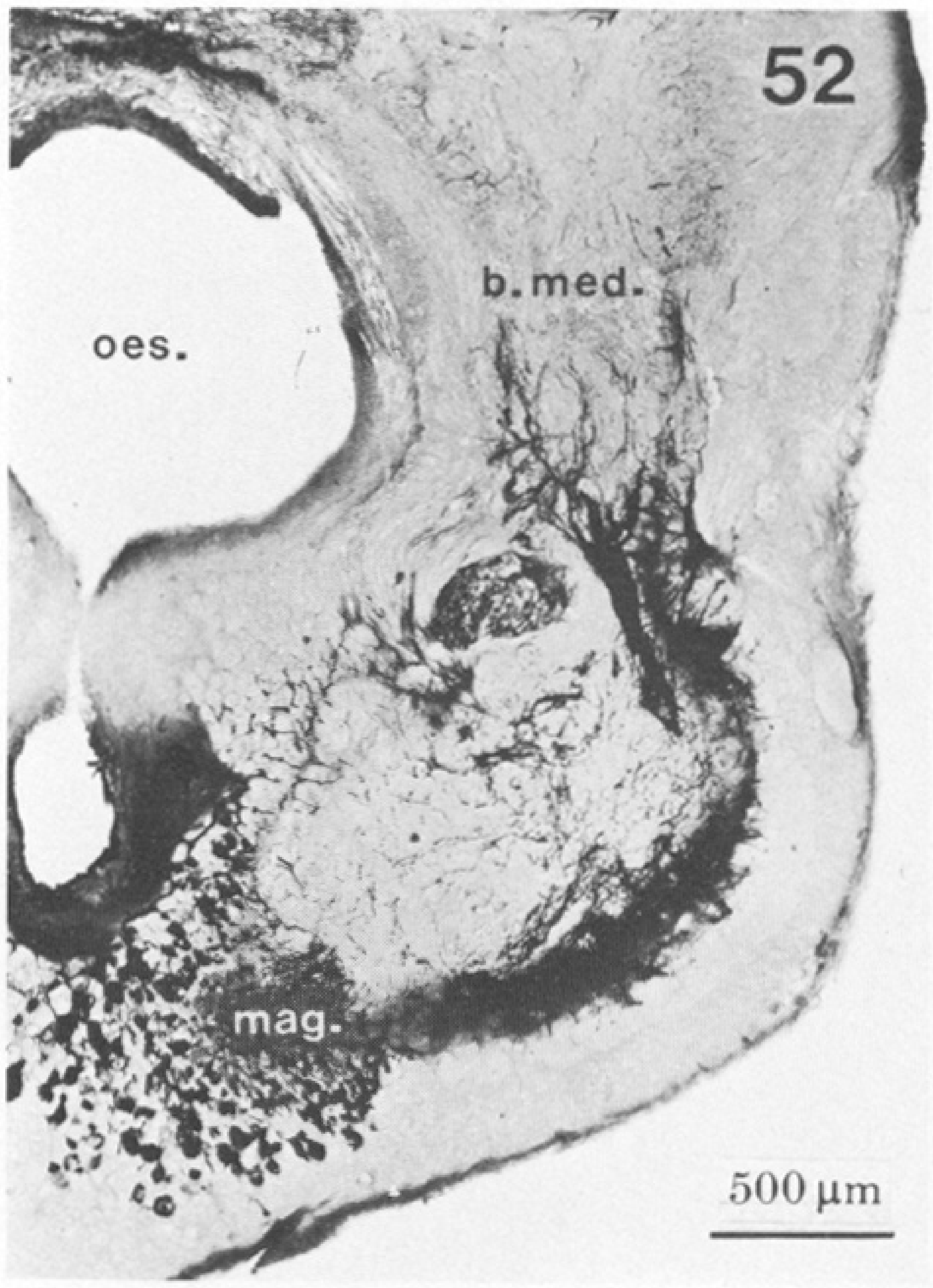

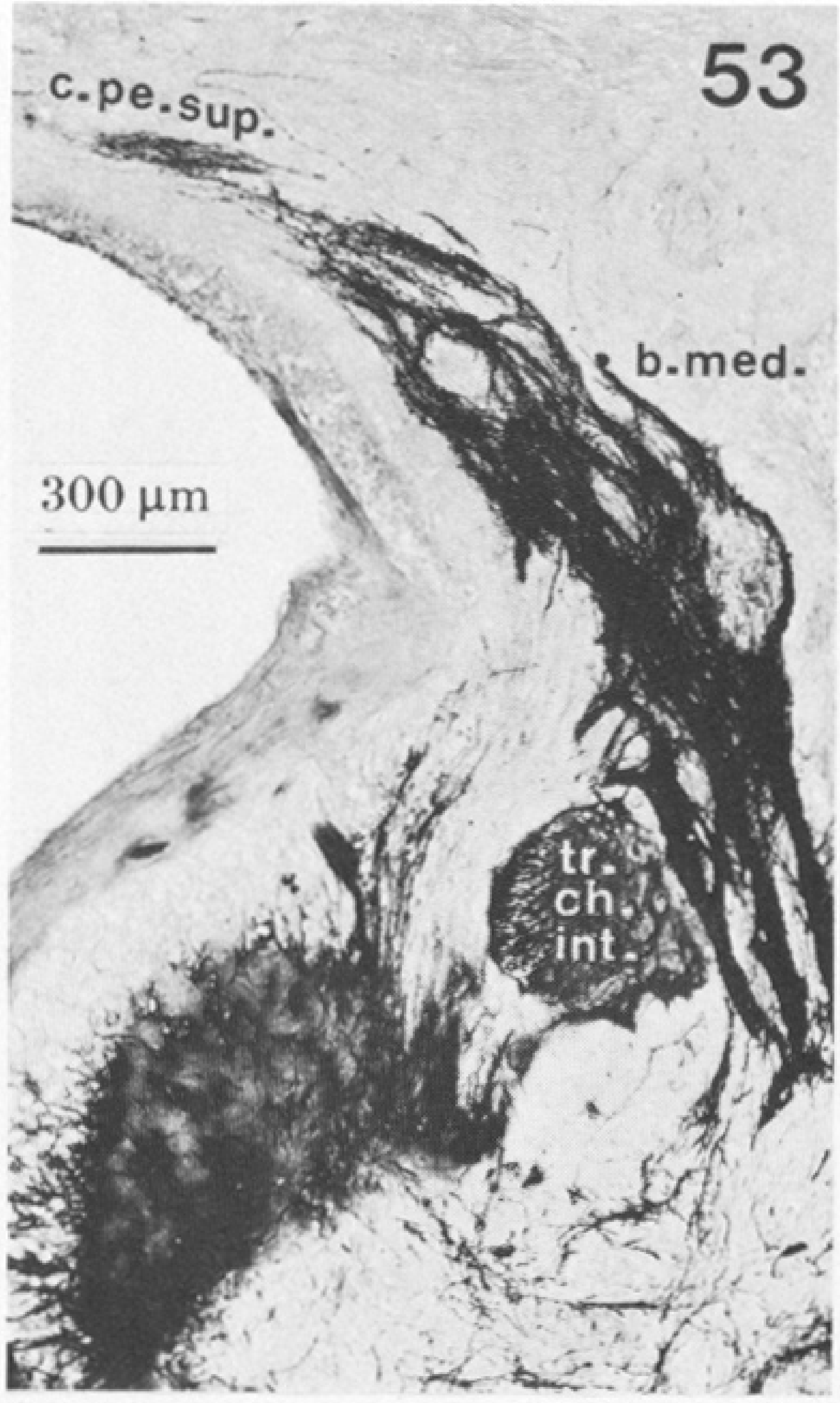

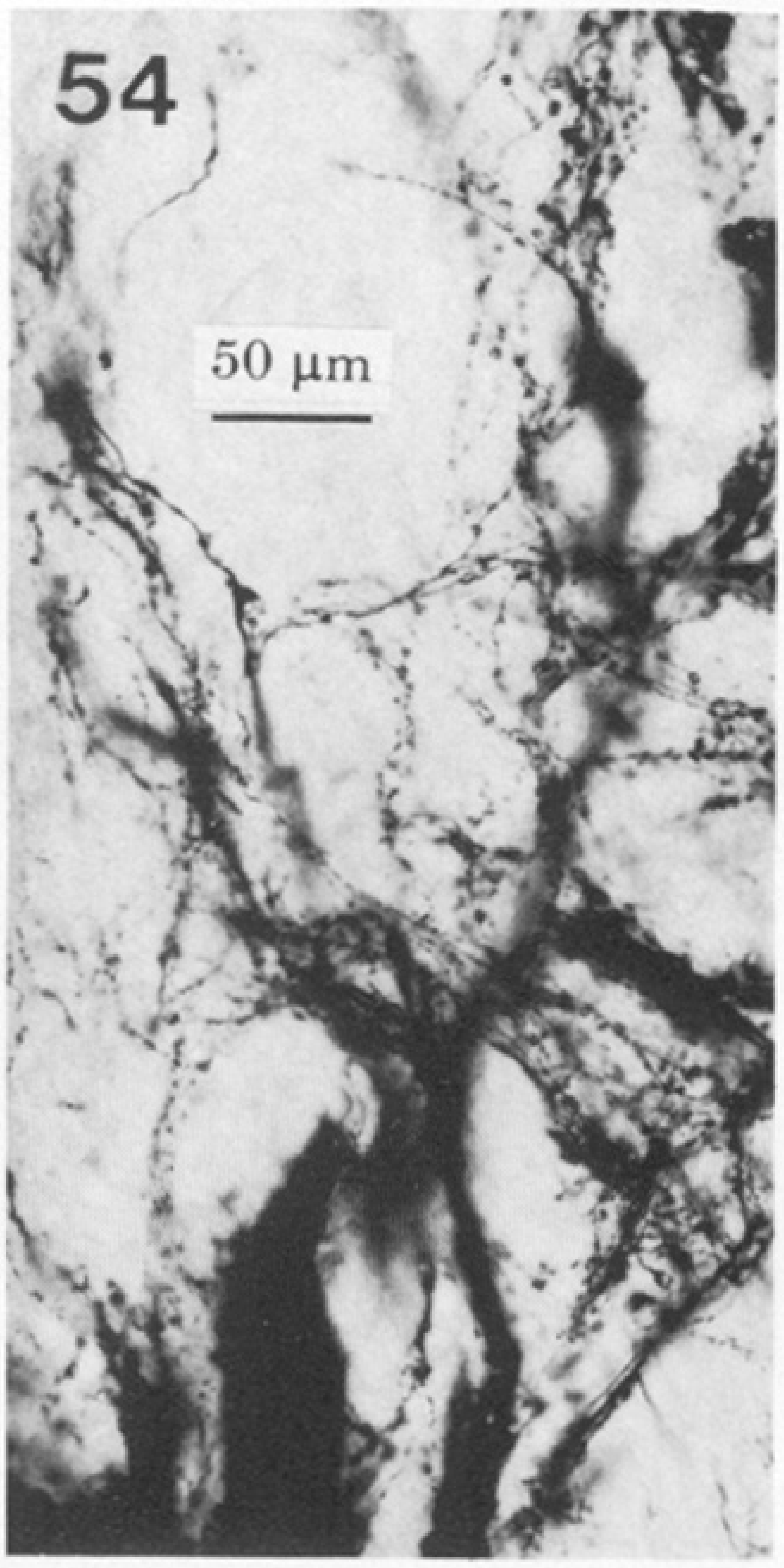

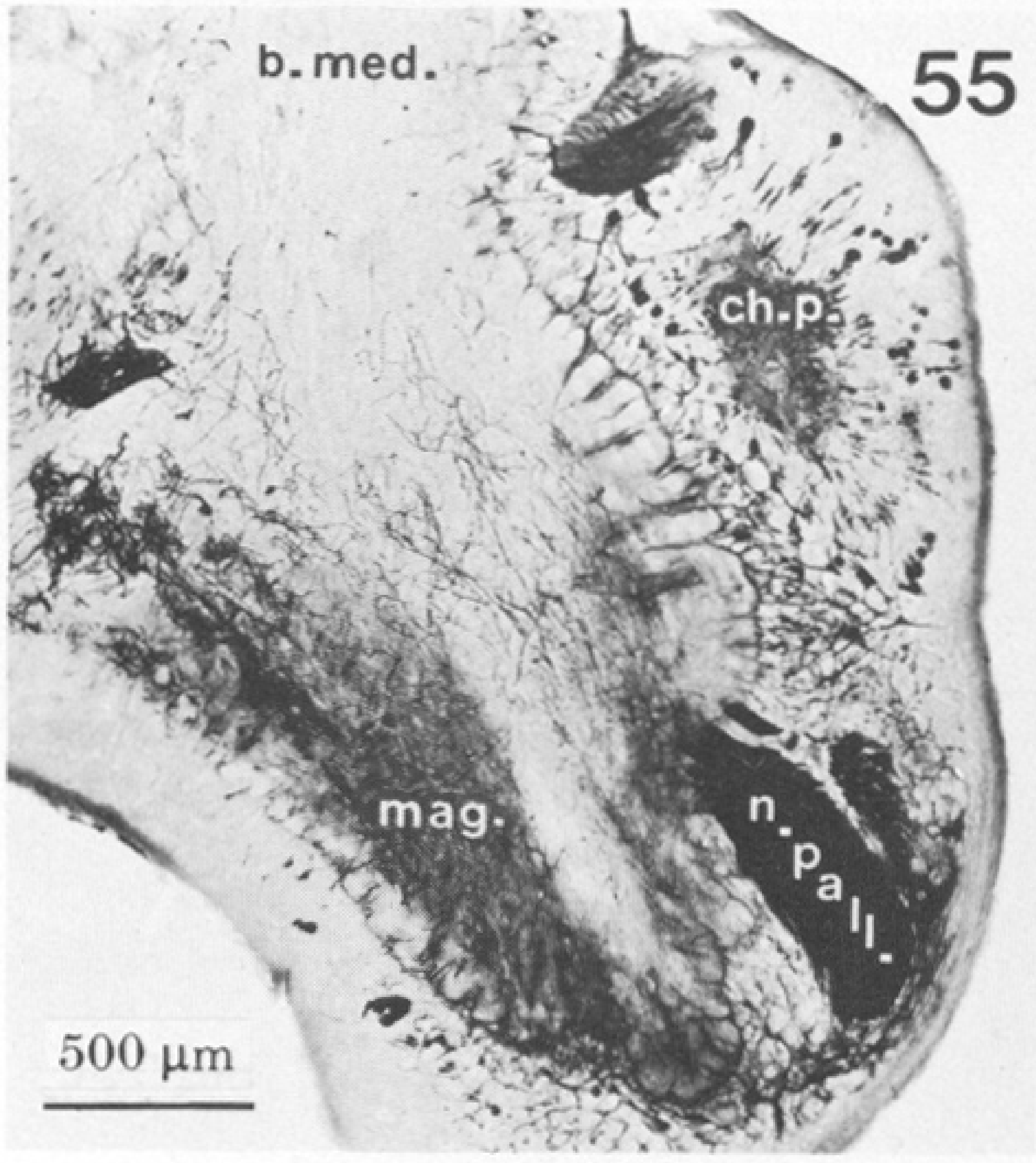

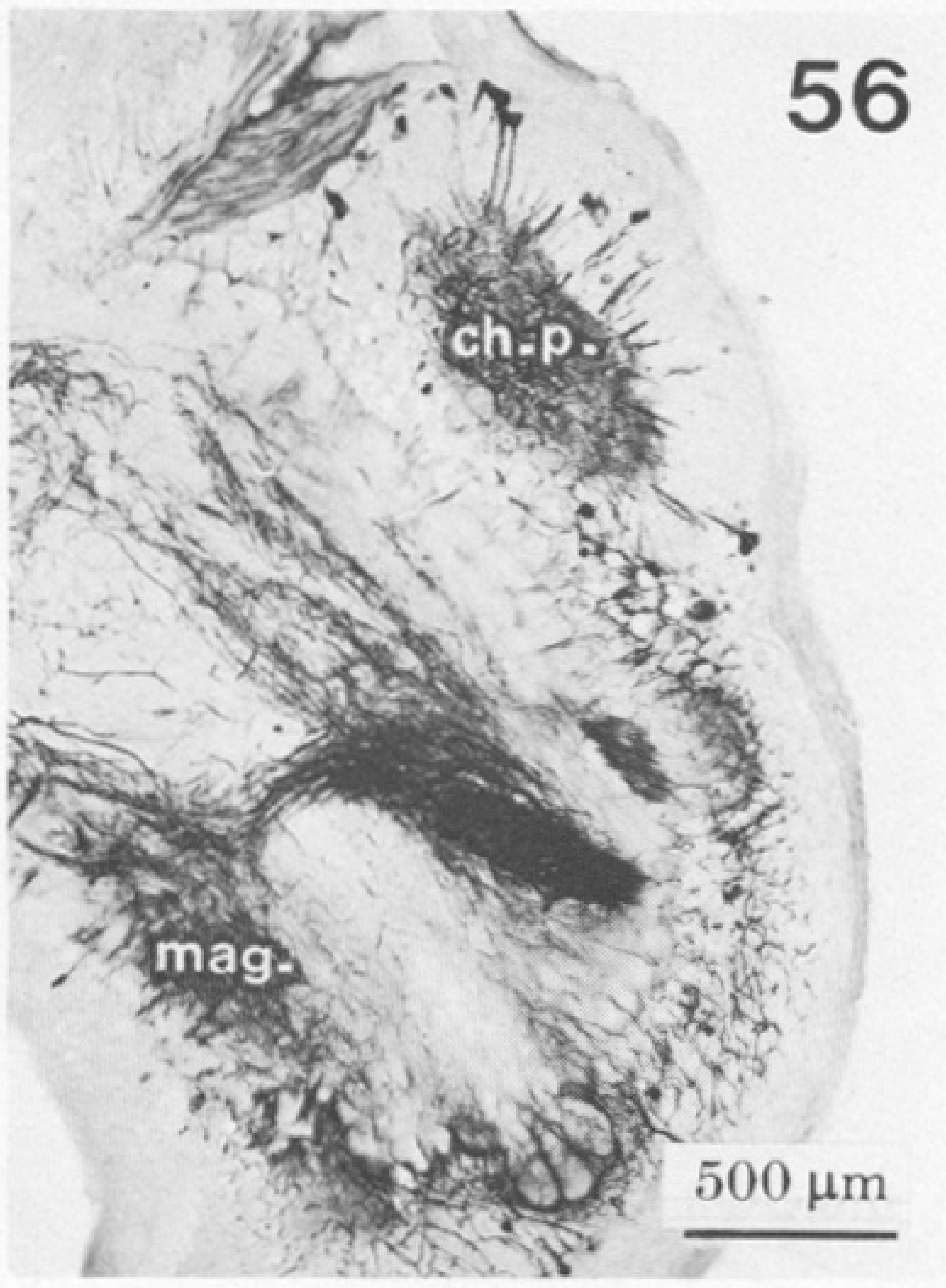

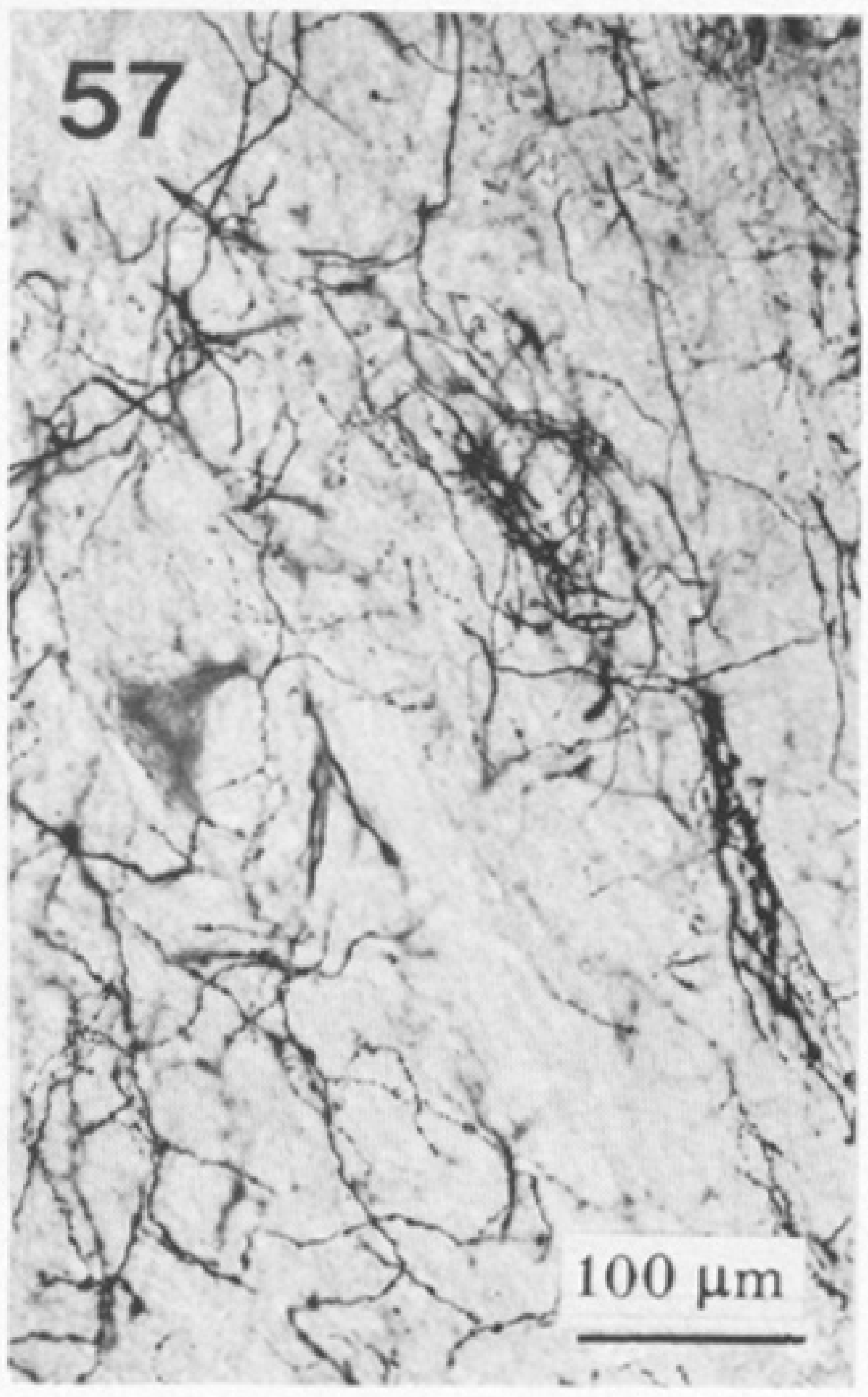

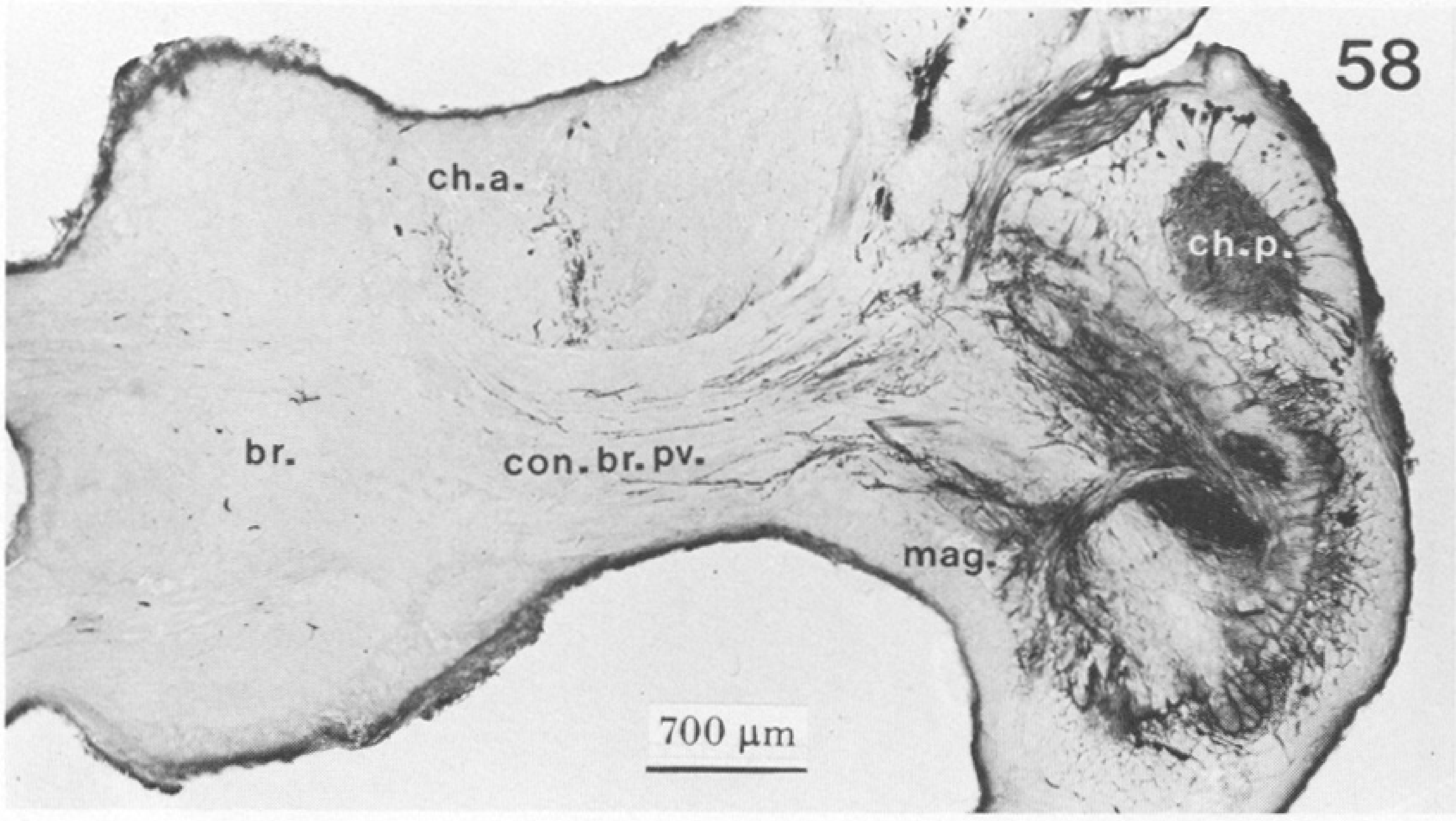

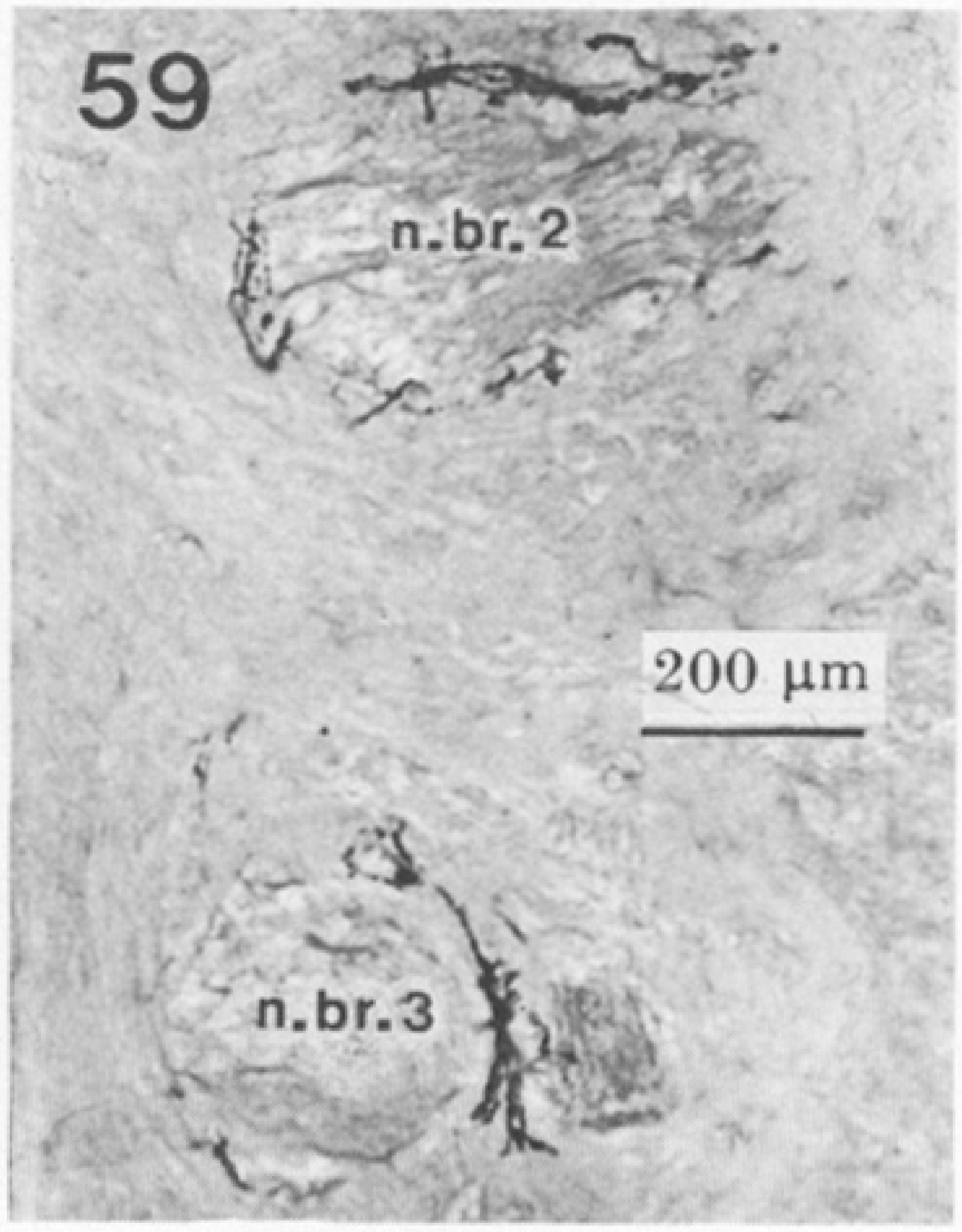

FIGURES 52–59. For description see opposite.